

## CASE REPORT

# Bilateral Ischial Tuberculosis

<sup>1</sup>Mandeep S Dhillon, <sup>2</sup>Mandeep S Virk, <sup>3</sup>Sarvdeep S Dhatt

## ABSTRACT

A unique case of bilateral ischial tuberculosis is presented with discussion of mode of spread of the case. Early diagnosis is mandatory for good results, and with a worldwide resurgence of the disease, a high index of suspicion is necessary. Magnetic resonance imaging (MRI) is helpful for defining the exact extent of the disease and response to treatment.

**Keywords:** Ischial, Magnetic resonance imaging, Osteoarticular, Polymerase chain reaction, Tuberculosis.

**How to cite this article:** Dhillon MS, Virk MS, Dhatt SS. Bilateral Ischial Tuberculosis. *J Postgrad Med Edu Res* 2016;50(4):197-198.

**Source of support:** Nil

**Conflict of interest:** None

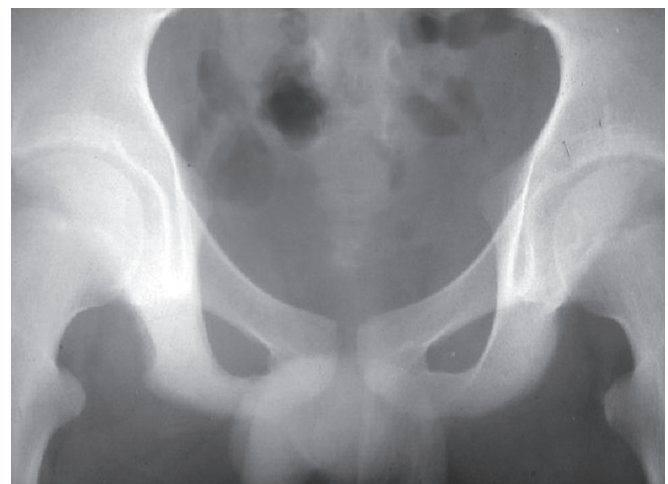## CASE REPORT

An 18-year-old male presented with pain in both gluteal regions of 4 months duration. He complained of on and off episodes of low-grade fever with insignificant loss of weight and normal appetite. There was no history of contact with any tuberculous patient in or outside the family. General examination revealed pallor with no regional significant lymphadenopathy. Clinical examination revealed tender swellings in the gluteal regions over the ischial tuberosities. They were deep-seated, globular, cystic, and nonpulsatile with ill-defined margins. Hips were pain-free in the most of the range of motion except for flexion beyond 80° and terminal internal rotation. Functionally, the patient was not able to sit on hard surfaces. There was also inability to balance while trying to squat. Sacroiliac joints, lumbo-sacral spine, and knees were normal.

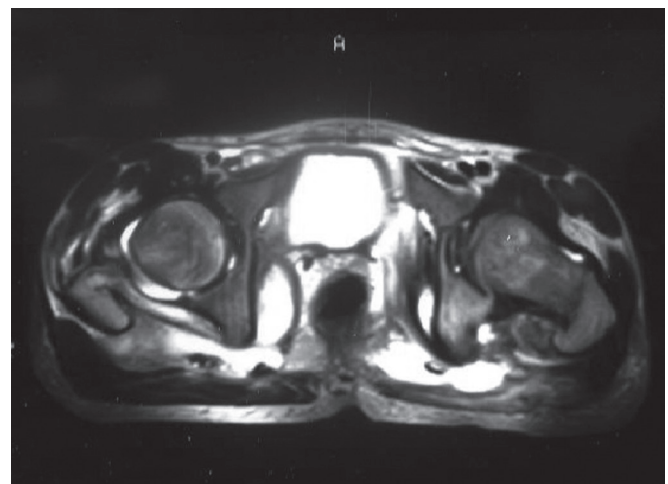
Laboratory tests revealed hemoglobin of 9.8, ESR of 40 mm first hour westergren, total leukocyte count of 11,000, with a predominance of lymphocytes. Mantoux test gave an induration of 36 mm. X-rays revealed lytic

lesion on left side and on the right side margins were indistinct (Fig. 1).

Magnetic resonance imaging (MRI) revealed involvement of both the ischial tuberosities with changes in signal intensity suggesting granulomatous pathology (Fig. 2). There were collections in various intrapelvic and extrapelvic planes bilaterally. Diagnostic confirmation was done by histopathological examination and polymerase chain reaction (PCR) of the aspirate obtained by computed tomography (CT)-guided fine-needle aspiration cytology from one of the lesions that showed epithelioid granulomas and grew the genome of mycobacteria respectively. However, mycobacteria could not be cultured.



**Fig. 1:** X-rays of pelvis with both hips show lytic lesion on left side and on the right side margins were indistinct



**Fig. 2:** Magnetic resonance imaging revealed involvement of both the ischial tuberosities with changes in signal intensity and collections in various intrapelvic and extrapelvic planes bilaterally

<sup>1</sup>Professor, <sup>2</sup>Resident, <sup>3</sup>Assistant Professor

<sup>1,3</sup>Department of Orthopaedics, Postgraduate Institute of Medical Education and Research, Chandigarh, India

<sup>2</sup>Department of Orthopaedics, The New England Musculoskeletal Institute University of Connecticut Health Center, Connecticut American Samoa

**Corresponding Author:** Mandeep S Dhillon, Professor Department of Orthopaedics, Postgraduate Institute of Medical Education and Research, Chandigarh, India, e-mail: drdhillon@gmail.com

The patient was started on four drugs of antitubercular therapy comprising Rifampicin (10 mg/kg), Isoniazid (5 mg/kg), Pyrazinamide (25 mg/kg), and Ethambutol (15 mg/kg). During the course of treatment, the hip became pain-free in full flexion and also terminal internal rotation. The pain that occurred on sitting vanished and hamstring spasm got relieved. The treatment was carried for a total of 18 months. At the time of last follow-up, the patient was totally symptom-free. Review of MRI scans showed signs of healing tuberculosis.

## DISCUSSION

Due to uncommon nature of osteoarticular tuberculosis, presentation at unusual sites like the ischium may be even more difficult to diagnose and can present to the hospital very late.<sup>1</sup> This can lead to increasing damage even to the extent that acetabulum can get involved theoretically risking the hip joint.<sup>2</sup>

Ischium is one of the rare sites to be involved by mycobacterium tuberculosis.<sup>3</sup> The incidence is generally not more than 0.2% in any of the large series. The most common mode of presentation of ischial tuberculosis is pain with multiple sinuses or fistulas.<sup>2</sup> Ischial tuberculosis was reported in patients as young as 6-year-old boy by Samar et al.<sup>4</sup> Paratracheal lymphadenopathy was present along with the bone lesion.<sup>4</sup> According to the age of the patient, a differential diagnosis of primary bone neoplasm, metastasis should initially be made. The workup should also rule out ischial osteitis, osteochondritis in adolescents, lesions of the pubic symphysis in athletes, and postpartum infection in women.<sup>5</sup>

Ischium does not form part of any joint but due to certain anatomical reasons the pathologies are detected early. First, it bears weight while sitting and is prone to direct pressure causing pain. Secondly, hamstrings take origin from ischiums that go into spasm whenever there is inflammation in relation to it. Our case could not squat because of hamstring spasm, leading to the ground reaction force falling posterior to the center of gravity.

Polymerase chain reaction is a highly sensitive modality of detecting mycobacterial infections but with care the test sample is representative of the lesion and is adequately collected and processed. Minimally invasive procedures like CT or ultrasound-guided aspirations prove to be very handy in these situations. Positive PCR mandates start of antitubercular therapy even if mycobacteria are not grown provided that clinical and radiological suspicion exists. Other tests like ESR, Mantoux test, enzyme-linked immunoassay sorbent assay can only play a supportive role.

Mycobacteremia and seeding of multiple sites in the body is common in HIV patients. Multiple site involvement should arouse the suspicion of immunodeficient states and efforts towards detection of the same. HIV is

the leading risk factor for reactivation of latent disease.<sup>6</sup> The index case was investigated for immunodeficiency states and proved negative.

The treatment of osteoarticular tuberculosis is primarily medical.<sup>7</sup> Surgical treatment is reserved for cases where diagnosis is in doubt, inadequate results of therapy, and presence of large abscesses and recrudescence in spite of treatment.<sup>8</sup> The benefits being three-fold: One, tissue diagnosis is obtained; two, drug sensitivity patterns can be done if it is a case of multiple drug-resistant tuberculosis; and three, the disease load is reduced by debridement. In a case of ischial tuberculosis seen by Kwon et al,<sup>9</sup> only surgical treatment initially resulted in recurrence of the lesion after 8 years. The lesion settled only after a combined antitubercular therapy along with surgical debridement.<sup>9</sup>

The bilateral presentation of ischial tuberculosis is unique and to the best of our knowledge has not been reported in international medical literature. Mode of spread is generally hematogenous from a primary site, as might have been in our case but the spread to the opposite side could be contiguous involvement by the pus that was present in various planes both inside and outside the pelvis.

In conclusion, ischial tuberculosis as a rare skeletal site for tuberculosis is well established. Bilateral involvement is not only rare but also first of its kind in ischium. Paralleling the increasing incidence of HIV, involvement of rare and multiple skeletal sites by tuberculosis is also increasing. Early diagnosis and treatment is the key to optimal functional outcome. To diagnose these lesions, PCR and MRI prove to be valuable aids.

## REFERENCES

1. Krishnan H, Yoon TR, Park KS, Cho YJ. Ischial tuberosity tuberculosis: an unusual location and presented as chronic gluteal abscess. *Malays Orthop J* 2010;4(1):42-45.
2. Milch H. *Injuries and surgical diseases of the ischium*. New York (NY): Hoeber-Harper Book; 1958. p. 104-112.
3. Tuli SM. *Tuberculosis of skeletal system*. 2nd ed. New Delhi: Jaypee Brothers Medical; 2000. p. 156-159.
4. Samar G, Eghrari M, Saebi E. Tuberculosis of the ischium. *Indian J Pediatr* 1985 May-Jun;52(416):321-322.
5. Garcia S, Segur JM, Combalia A. Tuberculosis of the ischium. *Acta Orthop Belg* 1994;60(2):238-240.
6. Kox LF, van Leeuwen J, Knijper S, Jansen HM, Kolk AH. PCR assay based on DNA coding for 16S rRNA for detection and identification of mycobacteria in clinical samples. *J Clin Microbiol* 1995 Dec;33(12):3225-3233.
7. Watts HG, Lifeso RM. Current concepts review. Tuberculosis of bones and joints. *J Bone Joint Surg Am* 1996 Feb;78(2): 288-298.
8. Dhillon MS, Gupta R, Rao KS, Nagi ON. Bilateral sternoclavicular joint tuberculosis. *Arch Orthop Trauma Surg* 2000;120(5-6):363-365.
9. Kwon SE, Jung IH, Kim DH. Tuberculosis infection of the ischial tuberosity and that recurred after 8 years – a case report. *J Korean Hip Soc* 2011 Mar;23(1):79-82.