

Clinicopathological Conference Report

pANCA Positive Classic Polyarteritis Nodosa

CPC Editor : Prof Nandita Kakkar
CPC Chairperson : Prof Vinay Sakhuja
Clinician Incharge : Prof Surjit Singh
Clinical Discussant : Prof Vivek Lal
Pathology Discussant : Prof RK Vasishta

This case was discussed on 27th July 2011, as a staff clinicopathological exercise at PGIMER, Chandigarh, India

Clinical Protocol and Case Analysis (Prof Vivek Lal)

This 62 years old male presented with progressive weakness of upper and lower limbs since 3 months which was subacute, asymmetrical in onset and painful. It began on the right side and went over to the left (Rt UL → Rt LL → Lt UL and LL) but there was no bladder involvement. He had associated low grade fever off and on. He received IV steroids (alternate day dexamethasone injection) followed by transient improvement. There were 6 to 7 episodes of malena and the steroids were stopped. There was decreased urine output since 1 month associated with vomiting, generalized edema and subsequently he lapsed into altered

sensorium. He was unable to recognize his relatives and would talk incoherently. There was h/o bronchial asthma since 10 years. There was no history of cranial nerve palsies, headache, seizures or hemiplegia. No h/o cough, expectoration, hematuria, jaundice, joint pains, rash, oral ulcers and photosensitivity. He was a reformed smoker and an occasional alcohol consumer.

On examination, he was drowsy, disoriented, afebrile, pulse 86 per minute BP—120/80 mm Hg and respiratory rate was 18/minute. There was pallor, pitting edema, clubbing, b/l basal crepitations, CNS status was E3-4 V5M6 with left LR palsy, right UMN 7th nerve palsy, wasting of b/l intrinsic hand muscles, hypotonia of all four limbs,

Table 1: Investigations

	12/5	16/5	18/5	20/5	
Hb	8.3	7.8	6.9	7.1	
TLC	12,700	14,800	29,400	21,500	
DLC, P/L/M/E	76/20/3/1	77/19/2/2	81/14/3/2	94/3/1/2	
Platelets	159 × 10 ³	202 × 10 ³	244 × 10 ³	195 × 10 ³	
ESR-60	PBF—Anisocytosis, poikilocytosis, hypochromia				
	12/5	16/5	18/5	21/5	22/5
BU/Creat	91.8/3.3	98.8/3.69	127.25/4.81	106.4/3.87	76/2.8
S. Na ⁺ /K ⁺	144/3.77	135/5.79	136.7/6.32	131/3.76	131/3.0
S. Ca ⁺⁺ /P	7.8/7.9	7.5/6.7	8.8/10.8	8.6/7.4	
S. Protein/Alb	5.2/1.9	5.2/2	5.6/1.7	6/2.3	
T. Bil.	0.56	0.80	1.11	0.84	
SGOT/PT	34.2/31.1	19.31/16.09		14.29/12.97	
S. ALP	919	1450	1065.36	735	
S. Uric acid	8.87	9.28	10.43	9.53	
TSH	7.54				
Viral markers	–ve				
T. Chol	93				
TGs	140				
LDL	34.98				
HDL	38.7				
S. Mg ⁺⁺	2.2	1.74		2	
Urine R/E	RBC+++ 15-20 pus cell	RBC+++ 7-8 pus cell			
pH	7.413	7.217	6.877	7.124	7.322
Po ₂	63.7	228.4	70.8	169.6	160
Pco ₂	23.5	43.6	98.5	53.7	35.7
HCO ₃	14.7	17.3	17.9	17.2	18.1
SpO ₂	91.8%	99.6%	71.6%	98.6%	99.2%
BE	–7.7	–10.1	–17.5	–12.3	–7.1

power—Gr 0/5 in Rt UL/LL and Gr 3/5 in left UL/LL, b/l wrist drop present and generalized areflexia with mute planters.

Other Investigations

Blood C/s: Methicillin resistant *Staphylococcus aureus* (outside PGI); Sterile × 3 (PGI); Urine c/s—sterile, fungal serology—negative, ANA negative, p ANCA++ by immunofluorescence and Elisa, HIV-nonreactive, SPEP—no M band, BJ proteins negative, PTI—100%, INR—1.01, APTT—45, fibrinogen—4.91 gm/l, D—dimer positive, NCS—sensorimotor polyneuropathy predominantly axonal, LL > UL (done outside); CSF—no WBCs, RBC++, protein—39, sugar—41; Gram stain: – ve

Radiology: NCCT head revealed (L) basal ganglia infarct; MRI brain revealed acute focal infarcts in left basal ganglia and left paraventricular white matter, MRI cervical spine: NAD, no cord compression; CT chest (plain): Patchy nodular opacities b/l lower lobes (Rt > Lt, posterior segments), likely infective. Minimal right sided pleural effusion. CT abdomen (plain)—suspicious thickening of colonic wall with subtle pericolonic stranding? Inflammatory, USG abdomen—moderate ascites, mild peri cardiac and b/l pleural effusion, mild hepatomegaly, b/l mildly increased renal cortical echogenicity, Compression USG b/l LLs—no evidence of DVT.

Course and management: Patient underwent upper GI endoscopy for UGI bleed. Found to have duodenal ulcer and he underwent cautery. Received blood transfusions, antibiotics, amphotericin and later three sessions of hemodialysis outside. After admission, he was managed on the lines of vasculitis, renal failure (underwent peritoneal dialysis), hyperkalemia, sepsis and septic shock (antibiotics, inotropes and peritoneal dialysis). He developed cardiac arrest on 17.5.2011, was revived, but succumbed to a second cardiac arrest on 23.5.2011.

Units final diagnosis: Mononeuritis multiplex, diffuse cerebral infarctions? Polyarteritis nodosa? Microscopic polyangiitis, severe sepsis, acute kidney injury, refractory septic shock.

Case Analysis

The patient had a background history of bronchial asthma for past 10 years. In the present illness, he had peripheral and cranial neuropathy along with acute kidney injury and alteration of sensorium. Peripheral and cranial neuropathies were evident on clinical examination. Acute kidney injury was evident from oliguria, elevated creatinine, presence of active urine sediment and USG suggestive of acute renal

dysfunction. Alteration sensorium apparently was because of CNS infarcts which is debatable as the infarcts are too small, and CSF analysis was normal. Above all, he had a strongly positive pANCA and MPO Elisa with a reading of 2.4 (cut of being 0.4).

Generally, when vasculitic diseases involves the nervous system, the peripheral nervous system is the first to get involved. PNS is 10 times more commonly involved than CNS. CNS involvement is most often delayed and infarction is the commonest abnormality far exceeding hemorrhage. Hypertension plays a concomitant role in causing CNS infarcts. This patient is not a known hypertensive or diabetic and so the CNS infarcts which were present could possibly be due to vasculitis.

The patient had asymmetrical onset weakness of one limb that progressed to involve the rest of the limbs. Did the patient have sensorimotor polyneuropathy or did he have mononeuritis multiplex that is the question. It is important to differentiate between these two.

Asymmetrical onset and weakness favors mononeuritis multiplex and is a feature against peripheral neuropathy. Presence of associated pain along with weakness is again a feature of mononeuritis multiplex. Peripheral neuropathies are length dependant and lower limbs are involved before upper limbs. In mononeuritis multiplex, upper limbs can be involved before the lower limbs, as was in this case. This patient had a wrist drop. Presence of wrist drop favors mononeuritis multiplex. Wrist drop occurs because of differential weakness of wrist extensors and wrist flexors being spared. In peripheral neuropathy, this differential weakness is not seen and both wrist flexors and extensors are equally affected. Nerve conduction study showed involvement of median nerve with ulnar nerve being spared. Selective nerve involvement is a feature of mononeuritis multiplex.

Patient also had ophthalmoparesis due to 6th nerve palsy. First thing in a patient with 6th nerve palsy is to rule out raised ICP. The patient did not have headache, seizures, papilledema and CT did not show any significant cerebral edema. So in all probability, the involvement of 6th nerve is a part of vasculitic process and is not a false localizing sign. Cranial nerve involvement in vasculitic illness is most common in SLE followed by Wegener's granulomatosis, rheumatoid arthritis and others. There is nothing to suggest for the cause of 6th nerve palsy. Possibility of ischemia is far more common than a granuloma in causing the 6th nerve palsy.

ANCA positive vasculitis comprises Wegener's granulomatosis, microscopic polyangiitis and Churg-Strauss syndrome. Bronchial asthma is most prominent feature of CSS and present in almost 100% of patients. Wegener's

granulomatosis can be excluded in this patient as he had no involvement of upper respiratory tract, no sinus tenderness and no serosanguinous nasal discharge. In patients with CSS, asthma can precede other systemic manifestations by months to years, average period being 3 to 5 years. Blood eosinophilia is universal to be more than 10%. Sometimes only tissue eosinophilia is seen in the absence of blood eosinophilia, especially in those who have received steroids. It is unclear whether steroids alone would explain the absence of blood eosinophilia in this patient. Patients of CSS with ANCA+ have more ominous manifestations, like mononeuritis multiplex and RPGN, as compared to those with a negative ANCA.

Microscopic polyangiitis is also a small vessel vasculitis. Lung involvement occurs in the form of diffuse alveolar hemorrhage and cavitary lesions. Mononeuritis multiplex, glomerular injury and stroke can also occur.

To choose between CSS and microscopic PAN, features favoring microscopic PAN is the presence of anti-MPO antibody positivity. Features that are against CSS are the absence of eosinophilia and the long latency between the onset of asthma and the other systemic manifestations. These points favor microscopic PAN as a better possibility.

This patient had evidence of sepsis in the form of leukocytosis and blood culture showing growth of MRSA. However, a normal PTI elevated fibrinogen and a normal platelet count are pointers against sepsis.

Altered sensorium in this patient cannot be explained alone by the small infarcts. CNS dysfunction appears to be unrelated to the infarcts. Patient had diffuse neuronal inhibition because of sepsis and concomitant renal dysfunction.

Elevation in serum alkaline phosphatase and a CT abdomen showed a normal liver. So, this ALP elevation could be of intestinal origin due to mesenteric ischemia.

So, my final diagnosis is ANCA + vasculitis: Microscopic polyangiitis with mononeuritis multiplex, glomerulonephritis and altered sensorium.

Open House Discussion

- *Dr Aman Sharma:* All the possibilities discussed by Dr Lal were considered during life. What helps the clinicians to differentiate between different vasculitides is the EMA system proposed by Dr Richard Watts which takes into consideration the ACR criteria, Chapel Hill consensus classification system, ANCA and various other soft pointers. Taking help from the above system, the index patient had no soft pointers to suggest Wegener's granulomatosis like sinus involvement or fixed lung nodules. However, the presence of an active sediment with RPRF and pANCA positivity takes us

toward a diagnosis of microscopic polyangiitis and not PAN. Churg-Strauss disease can be ruled out as there is no blood eosinophilia but, at times, only tissue eosinophilia is seen and that diagnosis is in the domain of the pathologist.

- *Prof V Sakhuja:* GI involvement is certainly not very common in MPA, although we have seen it occasionally. On CT, we have seen a definite involvement of the colon in this patient. He also had a duodenal ulcer and I wonder if that also is due to the vasculitic process.
- *Prof Sanjay Jain:* The diagnosis of systemic vasculitis is not in doubt but the point is what type of vasculitis is it—primary or secondary? The colonic thickening tells us that the disease has been going on for some time. I would favor MPA but, if the PTTK was prolonged, we could think of thrombosis and here malignancy associated vasculitis would have been a possibility. Churg-Strauss disease without peripheral eosinophilia comes into the picture. Fungal infection is a possibility as he was on steroids and there are multiple infarcts in the brain.
- *Dr Manish Rathi:* I agree with the diagnosis of an ANCA associated vasculitis and favor MPA over Churg-Strauss disease. However, GI involvement is very uncommon in MPA. Colonic thickening here could be due to bowel wall edema as the patient had significant hypoalbuminemia and not because of pancolitis, which however can be differentiated radiologically. Hypoalbuminemia could be due to proteinuria. Urine examination showed RBCs and pus cells but there is no mention of proteinuria. The raised alkaline phosphatase here seems to be due to the liver involvement which is well-described in vasculitis.
- *Dr Dhiraj Gupta:* The pancolitis and clubbing are not fitting into the story of a primary vasculitis. I would think of a secondary vasculitis here. Granulomatous diseases like tuberculosis or sarcoid with mononeuritis multiplex can also be a possibility.
- *Dr Aman Sharma:* GI involvement occurs in vasculitides. We have seen patients labeled as IBD with ulcers on colonoscopy and these have eventually turned out to be systemic vasculitis. We have seen isolated granulomatous GI vasculitis as well. The pancolonic involvement here looking like mural thickening can occur with ischemic involvement of the gut due to vasculitis.
- *Prof V Sakhuja:* One thing odd about the colonic involvement is that the patient was totally asymptomatic as far as the GI system is concerned.
- *Prof DK Bhasin:* Crohn's disease can present with vasculitis but the story is not fitting in here as there is

no bleeding per rectum or any diarrhea. Dr Rathi had raised a question about the presence of colonic edema due to hypoalbuminemia but, in that case, both the small and large bowels should have been involved.

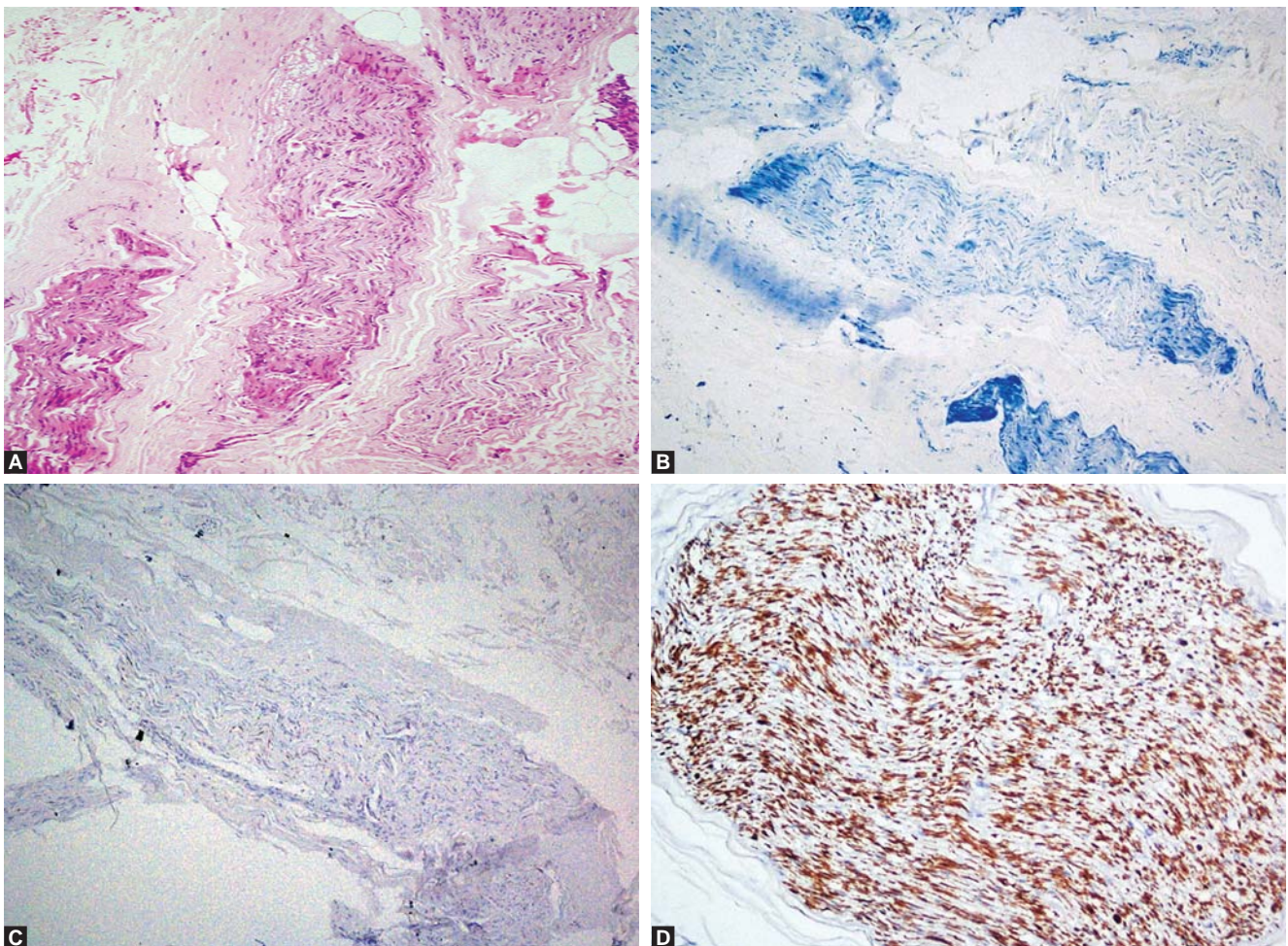
- *Dr V Sakhuja*: I now request Dr RK Vasishta to show us the pathological findings.

Pathology Discussion PM 24277:

Prof RK Vasishta

The antemortem sural nerve biopsy (S-7941/11) revealed demyelination with axonopathy (Figs 1A to D). A complete autopsy was performed. The pleural cavity contained 2 L of straw colored fluid. The kidneys (Fig. 2) weighed 240 gm. The capsular surface showed blotchy congestion and depressed scars. The cut section revealed medullary congestion and small pale infarcts. On microscopic examination, there were geographic areas of infarcts (Fig. 3A). The interlobar, arcuate and interlobular arteries showed vasculitis in the form of a spectrum of lesions of different ages present simultaneously. They began with

fibrinoid necrosis and acute inflammation, evolved through chronic inflammation and fibroplasias and culminated in varying degrees of vascular sclerosis, i.e. acute vasculitis (Fig. 3B), subacute vasculitis/healing vasculitis (Fig. 3C) and healed tombs of vasculitis (Fig. 3D) where the vessel was barely discernable. The internal elastic lamina was broken in the involved arteries (Fig. 4) and varying degrees of luminal occlusion due to intimal hyperplasia was seen. No glomerular lesions or any granulomatous lesions were noted. Interstitial inflammation was present. Immunofluorescence was negative for IgG, IgA, IgM, kappa, lambda, C3 and C1q. Electron microscopy did not show any immune deposits. pANCA was strongly positive by both immunofluorescence and Elisa [MPO Elisa—reading 2.4 (cut off of 0.4)]. Morphology was consistent with the diagnosis of classic polyarteritis nodosa. Extra renal small to occasionally medium sized vessels showed similar changes of vasculitis in the mesentery, liver, muscle, nerve, spleen and colon (Figs 5A to D). The brain weighed 1493 gm. Microscopic examination revealed small infarct in the left basal ganglia suggestive of subacute ischemia.



Figs 1A to D: Sural nerve shows (A) pale staining nerve, (B) myelin stain shows extensive loss of myelin, (C) IHC for neurofilament protein shows extensive axonal loss, (D) neurofilament positive control (A, H&E stain $\times 100$; B, myelin stain $\times 100$; C and D, immunoperoxidase, $\times 100$ and $\times 200$ respectively)

Atherosclerotic occlusion of a small branch of middle cerebral artery was also noted. Cerebral ischemia was present but no vasculitis was seen in the CNS. Early bronchopneumonia and pulmonary edema were noted. However, there was no capillaritis or any pulmonary

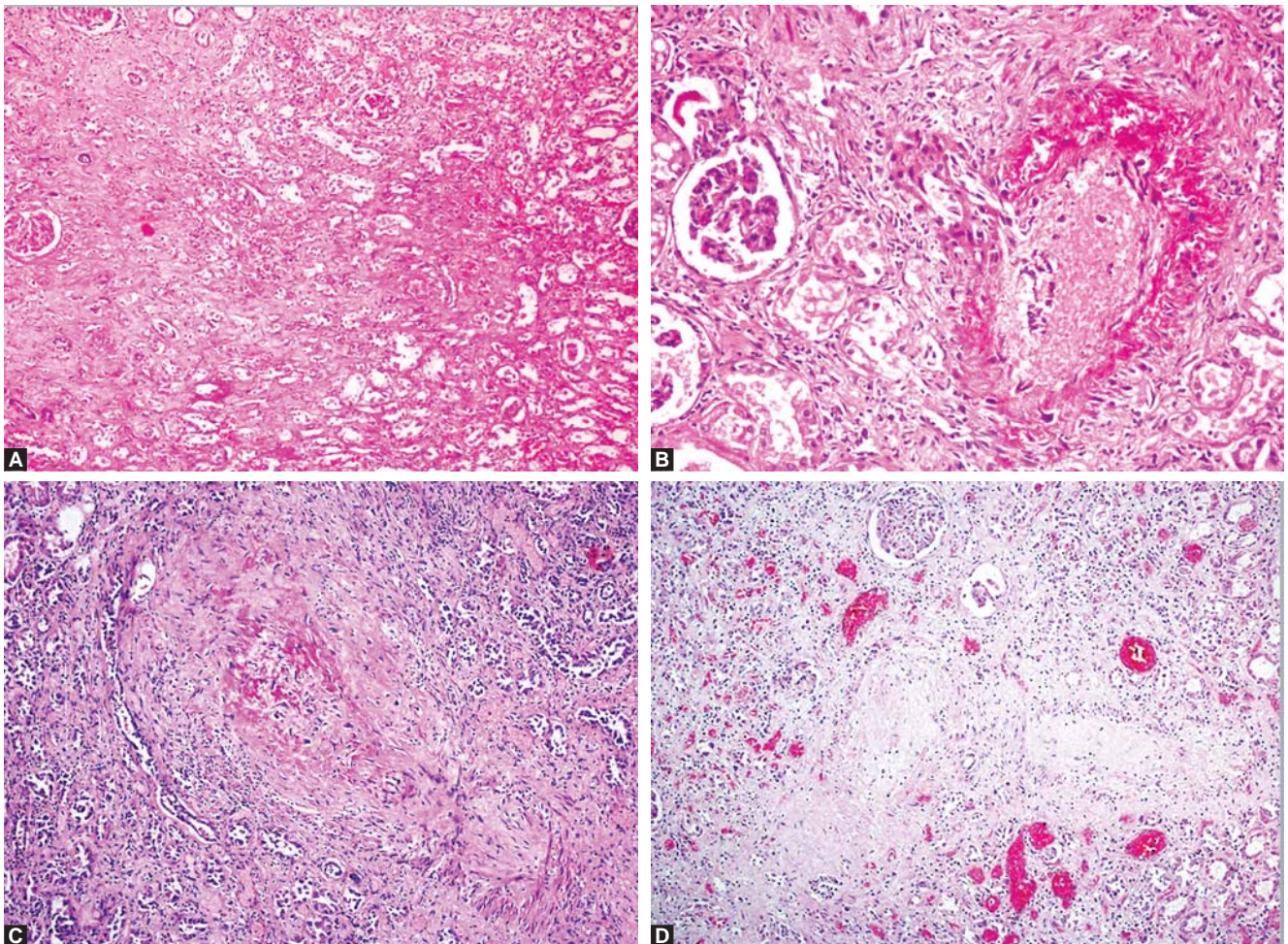
hemorrhage. Testes revealed testicular atrophy. In the jejunum, an incidental well-circumscribed tumor (4 × 4 × 3 cm) was seen on the serosal aspect and microscopy was consistent with the diagnosis of a benign gastrointestinal stromal tumor.

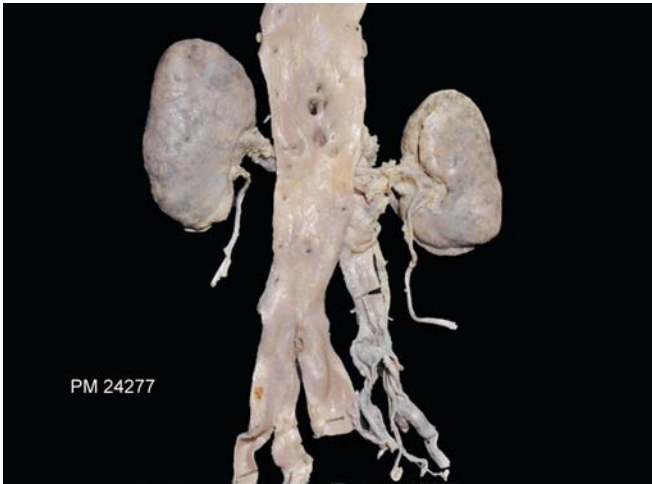

Fig. 2: Gross photograph of both the kidneys showing depressed scars and blotchy congestion

The Final Autopsy Diagnosis

- Classic polyarteritis nodosa (PAN)—p ANCA positive with vasculitis in the kidney, mesentery, muscle, spleen, liver and intestine
- Demyelination with axonopathy—Sural nerve
- Old infarct—left internal capsule—atherosclerotic with cerebral hypoxia
- Early bronchopneumonia, pulmonary edema, bilateral pleural effusion
- Grade II atherosclerosis—aorta
- Testicular atrophy
- Incidental gastrointestinal stromal tumor (GIST)—jejunum
- Organized thrombus—common iliac vein.



Figs 3A to D: Microphotographs from the kidney showing (A) infarct, (B) acute vasculitis with fibrinoid necrosis, polymorphs and nuclear debris present transmurally in a medium sized artery, (C) healing vasculitis seen in a medium-sized artery showing remnants of fibrin, occluded lumina, fibrosis and minimal inflammation, (D) healed vasculitis, i.e. tomb stones showing occluded lumina, fibrosis, minimal inflammation and no fibrin (H&E stain; A: ×40; B and C: ×200; D: ×100)

Open House Discussion

- *Dr V Sakhuja*: It is certainly a surprise to find classic PAN in this patient as on clinical ground, it was difficult to make this diagnosis due to the absence of hypertension, presence of pANCA positivity and the

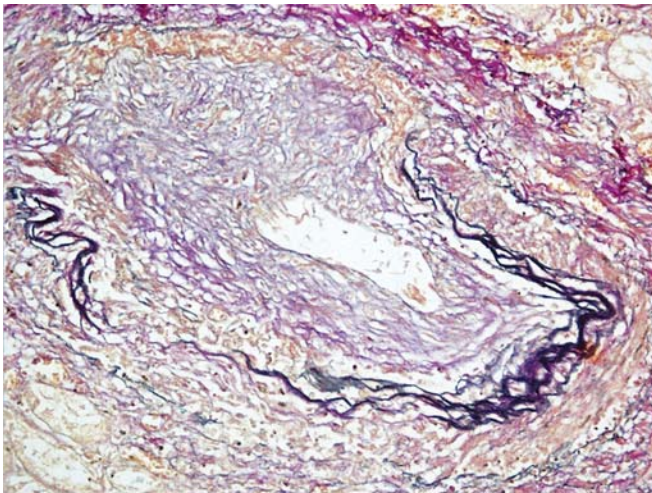
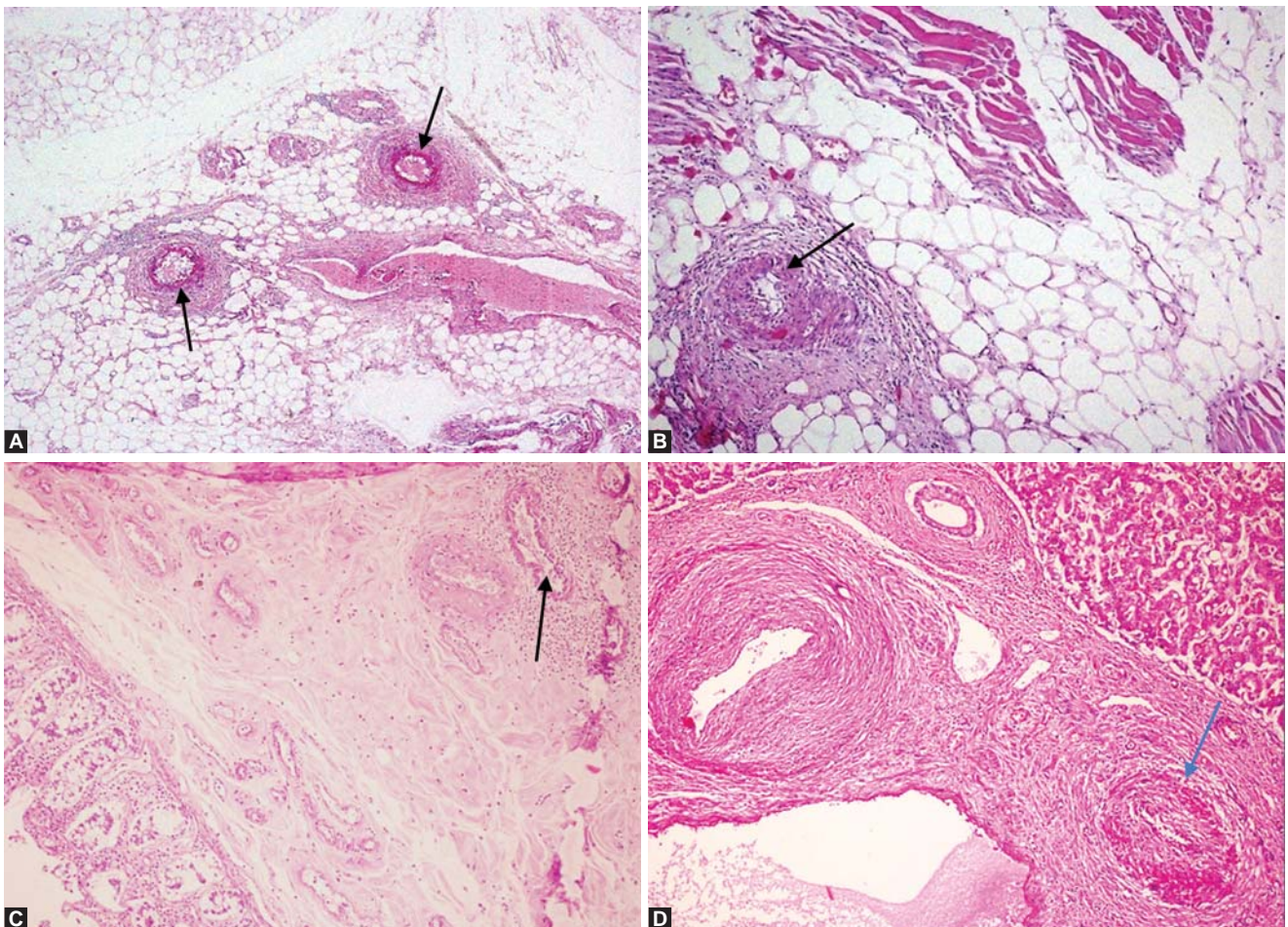


Fig. 4: Microphotograph of the kidney showing break of the internal elastic lamina, intimal proliferation with near total occlusion of the lumen in a medium-sized artery of the kidney (Elastic Van Gieson stain $\times 200$)

presence of RPRF which will only occur in PAN, if there are large bilateral multiple infarcts. We would have probably picked up the diagnosis, if contrast enhanced CT of the kidneys and CT angiography of the abdomen had been done.

- *Dr Sanjay Jain*: To me, it is not a surprise that this is case of classic PAN. Mononeuritis multiplex has a few causes only and classic PAN is one of them. A biopsy of the kidney here would have clinched the diagnosis.
- *Dr V Sakhuja*: Yes, but you cannot deny the fact that before the autopsy classic PAN was not even thought of.
- *Dr Manish Rathi*: It is surely a surprise to see classic PAN here. Urine will show RBCs in MPA routinely and, in classic PAN, only with large infarcts. If the USG had picked up the infarcts then PAN would have been thought of.
- *Dr V Lal*: Everything here is against the diagnosis of classic PAN as there is no hypertension, pANCA is positive, surface antigen negative and there is presence of renal injury.
- *Dr S Verma*: This debate about what type of vasculitis is present is always there in such cases and at times, we



Figs 5A to D: Acute vasculitis (arrows) in the (A) mesentery, (B) muscle, (C) colon, (D) liver

are lost in the maze of clinical findings until the pathologist opens the Pandora's box. Clinically, we were absolutely right in thinking of MPA more than classic PAN and here we have a classic PAN presenting as MPA. But, the issue is why the involvement of 7th nerve by the vasculitic process here should be called a lower motor neurone type of palsy.

- *Dr V Lal:* The 7th nerve palsy was a UMN type of palsy. During the hospital stay, this patient had a right hemiplegia which was missed due to the mononeuritis multiplex. That is the only way we can explain the 7th UMN involvement on the opposite side of left 6th nerve. The hemiplegia was on the right side and we see the infarct on the left side.
- *Dr RK Vasishtha:* There is no evidence of vasculitis in the CNS. The 6th and 7th nerve palsy could be due to the multiple microscopic infarcts that were present in the brain.
- *Dr Aman Sharma:* The major surprise in this case was the presence of pANCA positivity both by indirect immunofluorescence and enzyme-linked immunosorbent assay (ELISA) and both put together the specificity of small vessel vasculitis is exceptionally high in this case. But, work on the classification systems is on the way which will help the clinicians to classify better.
- *Dr Ranjana Minz:* pANCA positivity here is a big surprise and so we have to device our own systems and such patients have to be treated very aggressively.
- *Dr Sakhuja:* Thank you all very much.

COMMENTARY

Highlights of the Case

A 62-year-old male presented with fever, progressive weakness of both limbs, mononeuritis multiplex, malena, decreased urinary output, generalized edema and altered sensorium with left basal ganglia infarct. The pANCA was strongly positive and this led to a diagnosis of a small vessel vasculitis, i.e. microscopic polyangiitis. The autopsy however revealed a classic PAN. The point is whether pANCA is positive in classic PAN?

Classic Polyarteritis Nodosa (PAN)¹

The Chapel Hill nomenclature¹ defines PAN as necrotizing arteritis of medium-sized and small arteries without glomerulonephritis or vasculitis in arterioles, capillaries or venules. The major clinical manifestations of PAN are fever, peripheral neuropathy, myalgias, abdominal pain and signs and symptoms of renal disease. Most patients, however, present with nonspecific constitutional symptoms, such as fever, malaise, arthralgias, myalgias and weight loss. The

most common indicator of vasculitis is peripheral neuropathy which occurs in 75% of cases, typically in the form of mononeuritis multiplex. GI involvement occurs in approximately 50% cases in the form of abdominal pain and blood in the stool. Renal involvement manifests as flank pain and hematuria and occasionally as retroperitoneal hemorrhage from rupture of an aneurysm. Renovascular hypertension occurs in up to one third of patients. The gross abnormalities in the kidneys are the result of arterial pseudoaneurysms, thrombosis, infarction and hemorrhage. Any caliber artery in the kidney can be affected by PAN but the interlobar and arcuate arteries are involved most often. Microscopically, lesions of different ages may be observed simultaneously, i.e. acute, healing and healed vasculitic lesions. They begin with fibrinoid necrosis and acute inflammation, evolve through chronic inflammation and fibroplasia, and culminate in varying degrees of vascular sclerosis. Apart from the vasculitis, infarcts are seen but glomeruli are normal. Immunofluorescence microscopy and electron microscopy do not reveal evidence of vascular immune complex deposition. The etiology and pathogenesis of PAN is incompletely understood. There appear to be multiple causes and pathogenic mechanisms that can result in a pattern of arteritis that can be called polyarteritis nodosa. Less than 10% of patients with polyarteritis nodosa have serologic evidence for hepatitis B infection. Other infections that have been rarely associated with polyarteritis nodosa including hepatitis C, HIV and parvovirus B 19. ANCA is negative in classic PAN and thus does not play a role in its pathogenesis. ANCA is however positive in small vessel vasculitides, like microscopic polyangiitis, Wegener's granulomatosis and Churg-Strauss disease, where inflammatory involvement of capillaries or venules is present.²⁻⁵

pANCA positive Polyarteritis Nodosa

It is important to distinguish between MPA and PAN as they can lead to life-threatening complications and their treatment strategies and prognosis are different. ANCA are not frequent in patients who have arteritis that is not accompanied by inflammatory involvement of capillaries or venules and so ANCA is negative in classic PAN. But, in the index case, pANCA was positive by both indirect immunofluorescence and by Elisa. There are occasional case reports^{6,7} in literature stating the presence of pANCA positivity in classic PAN. They state that, when a patient presents with MPO-ANCA, alveolar hemorrhages and acute renal failure with little evidence of glomerulonephritis, a differential diagnosis of PAN should be made but it is finally the renal biopsy which will clinch the diagnosis. In the index

case, the kidney showed acute, healing and healed vasculitis in the medium sized arteries of the kidney (interlobar, arcuate) and multiple infarcts but no glomerular involvement was noted. However, in the extrarenal locations, i.e. the muscle, liver, spleen, colon, mesentery acute vasculitis were seen in the smaller arteries. Could this have led to the pANCA positivity is a matter of debate.

REFERENCES

1. Jennette CJ, Singh HK. Renal involvement in polyarteritis nodosa, Kawasaki disease, Takayasu arteritis, and giant cell arteritis. In: Jennette JC, Olson, Jean L, Schwartz, Melvin M, Silva, Fred G (Eds). *Hepinstall's Pathology of the Kidney* (6th ed). Lippincott Williams and Wilkins 2007;676.
2. Guillevin L, Lhote F. Distinguishing polyarteritis nodosa from microscopic polyangiitis and implications for treatment. *Curr Opin Rheum* 1995;7:20.
3. Guillevin L, Lhote F, Amouroux J, et al. Antineutrophil cytoplasmic antibodies, abnormal angiograms and pathological findings in polyarteritis nodosa and Churg-Strauss syndrome: Indications for the classification of vasculitides of the polyarteritis nodosa group. *Br J Rheumatol* 1996;35:958.
4. Lhote F, Guillevin L. Polyarteritis nodosa, microscopic polyangiitis, and Churg-Strauss syndrome: Clinical aspects and treatment. *Rheum Dis Clin North Am* 1995;21:911.
5. Kirkland GS, Savige JA, Wilson D, et al. Classical polyarteritis nodosa and microscopic polyarteritis with medium vessel involvement: A comparison of the clinical and laboratory features. *Clin Nephrol* 1997;47:176.
6. Sakaguchi Y, Uehata T, Kawabata H, et al. An autopsy proven cases of MPO-ANCA positive polyarteritis nodosa with acute renal failure and alveolar haemorrhages. *Clin Exp Nephrol* 2011;15:281-84.
7. Yamamoto T, Matsuda J, Kadoya H, et al. A cases of MPO-ANCA-positive polyarteritis nodosa complicated by exudative otitis media, mononeuritis multiplex and acute renal failure. *Clin Exp Nephrol* 2011;15:754-60.