

Reversal of Hartmann's Procedure in Patients with Very Short Rectal Stump: A New Technique

Gurpreet Singh, Vikas Gupta

ABSTRACT

Objective: Reversal of Hartmann's procedure is a difficult surgical exercise with significant morbidity and mortality. One of the difficulties encountered during surgery is the presence of a very short rectal stump.

Materials and methods: We present two cases where the patients underwent a Hartmann's procedure for abortion induced colonic injury and a subsequent failed attempt at reversal. The distal stump was mobilized from the sacrum (virgin field). An end to side anastomosis was performed between the distal end of colon and the posterior surface of the rectal stump using an end to end circular stapler.

Results: The patients had a complete recovery with good functional results.

Conclusion: This is a novel technique which when applied in such situations will prove technically easy and functionally adequate.

Keywords: Hartmann's procedure, Reversal, Short rectal stump.

How to cite this article: Singh G, Gupta V. Reversal of Hartmann's Procedure in Patients with Very Short Rectal Stump: A New Technique. *J Postgrad Med Edu Res* 2013;47(3):150-152.

Source of support: Nil

Conflict of interest: None declared

INTRODUCTION

Although initially developed in the 1920's for the treatment of rectosigmoid carcinoma, Hartmann's procedure is now performed for a variety of indications.^{1,2} Resection of the sigmoid colon in the emergency situation and the reluctance to perform an anastomosis on an unprepared colon is the main reason for the continued usage of this procedure. For patients who survive the onslaught of the initial surgery, closure of the stoma is a significant hurdle in their complete rehabilitation. Reversal of Hartmann's procedure is technically demanding and associated with significant morbidity and mortality. Although performed in the elective setting, operative mortality rates up to 10%, morbidity rates of 30 to 40%, and anastomotic leakage rates up to 15% have been reported.³

Only about two-third of patients may finally undergo colostomy closure.^{4,5} As a result, patients with stomas are forced to face many physical, psychological and social challenges, particularly in a developing country like India.^{6,7} This psychosocial impact of a permanent stoma is further aggravated when the index procedure was done for an underlying benign disease.

Several factors contribute to the complexity of reversal of Hartmann's procedure. These include managing intra-

abdominal adhesions, the need to perform a colorectal anastomosis, and the lack of familiarity with mobilization of the colon/rectum. One of the most difficult aspects of the reversal of a Hartmann's procedure is dissection of the rectal stump within the pelvis. We present two cases, where the reversal was abandoned by the initial operator due to failure to identify and mobilize a very small rectal stump, and also present our technique to overcome this difficulty.

MATERIALS AND METHODS

Two young females underwent an abortion at a community hospital. An iatrogenic uterine perforation and colonic injury resulted in postoperative fecal peritonitis. At emergency laparotomy a Hartmann's procedure was performed. They recovered from the illness and an attempt was made to close the stoma in the community hospital. The procedure was abandoned in view of the failure to identify and dissect the distal rectal stump. They attended our outpatient department 1 year later. With minor differences, both patients had a similar presentation and were evaluated and operated in an identical manner.

Both patients were in good health at presentation to our hospital. Their physical examination was normal except for the presence of the scar of previous surgery and an end colostomy in the left lower abdomen. Digital rectal examination revealed a very short rectal stump (closed end was palpable in both cases, making the length of the stump 7 cm or less) with good sphincter tone. The biochemical and hematological parameters were within normal limits. Contrast injected per rectum revealed a short distal rectal stump (7 cm) deep inside the pelvis (Fig. 1). Reversal of Hartmann's procedure was planned after explaining the options to the patient and obtaining consent for temporary ileostomy.

Patients were operated in a modified Lloyd Davis position with reverse Trendelenburg tilt. The rectum was tightly packed with roller gauze soaked with 5% povidone iodine solution to facilitate identification during surgery. The abdomen was accessed through an infraumbilical midline incision. The small bowel was freed from the pelvis and drawn cranially. The rectal stump was identified deep in the pelvis and was densely adherent to the posterior vaginal wall just below the level of the uterine cervix. No attempt was made to separate the dense anterior adhesions. The posterior rectal wall was dissected from the presacral fascia for a length adequate to accommodate a 33 mm

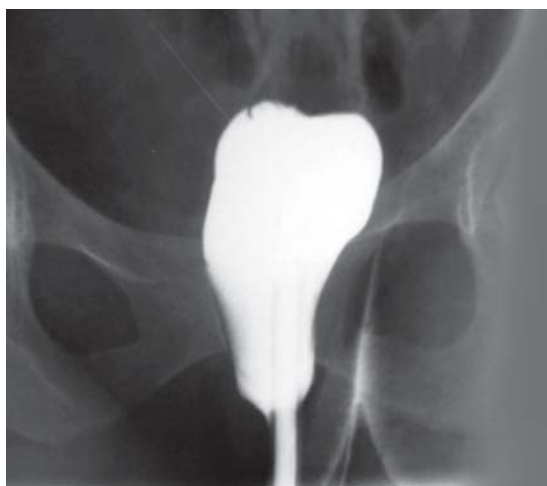

Fig. 1: Preoperative contrast study showing short rectal stump

circular stapler (CDH33, Ethicon). The proximal stoma was dismantled and mobilized adequately so as to reach the rectal stump without tension. The detached anvil was introduced into the proximal colon and the end closed around it. The stapling device was introduced per rectum and the trocar pin pierced through the posterior rectal wall. The stapling device was reassembled and fired creating a 33 mm stoma in the posterior rectal wall resulting in an end to side colorectal anastomosis (Figs 2 and 3). A diverting ileostomy was fashioned.

Both the patients recovered uneventfully. A contrast study per rectum was done 8 weeks later prior to closure of ileostomy (Fig. 4). Both patients are continent with a stool frequency of 1 to 2 stools per day almost 3 years after surgery.

DISCUSSION

The prevailing sociocultural values in India favor the birth of a male child. As a result, female feticide, though illegal, is still prevalent in this country. A study conducted by the Indian Council of Medical Research in rural India revealed the incidence of legal abortions to be 6.1 and illegal abortions to be 13.5 per 1,000 pregnancies, accounting for 12 to 20% of maternal deaths. Although no reliable data are available for illegal abortions, the total number of abortions per year in India is estimated around 6 million.⁸ Most illegal abortions are conducted without adequate facilities and by persons with no knowledge of anatomy and who operate with unsterile instruments.⁹ It is thus, not surprising that bowel injuries are associated with illegal abortions. Both our patients had a bowel injury as a result of abortion. The proximity of the rectum and sigmoid colon to the uterus makes them more vulnerable to such type of the injuries. The presentation is usually delayed till the patients develop peritonitis and sepsis. Primary repair or reconstruction is invariably not feasible in this setting. More often than not the distal rectal stump is usually deep inside the pelvis.

Reversal of the Hartmann's procedure is hazardous in these patients at all stages of the operation. Dense intra-abdominal adhesions due to prior peritonitis require the surgeon's attention and skill even before the main procedure. The tissue planes in the pelvis are usually difficult to dissect owing to the previous insult. In such a situation, dissection between the distal stump and anterior tissues (posterior vaginal wall and uterus) carry a substantial risk of injury and subsequent fistula formation. Additional technical difficulties include identification of a very short rectal stump and subsequent anastomosis. These difficulties are compounded, if reversal of Hartman's has been attempted, as was the case in both our patients.

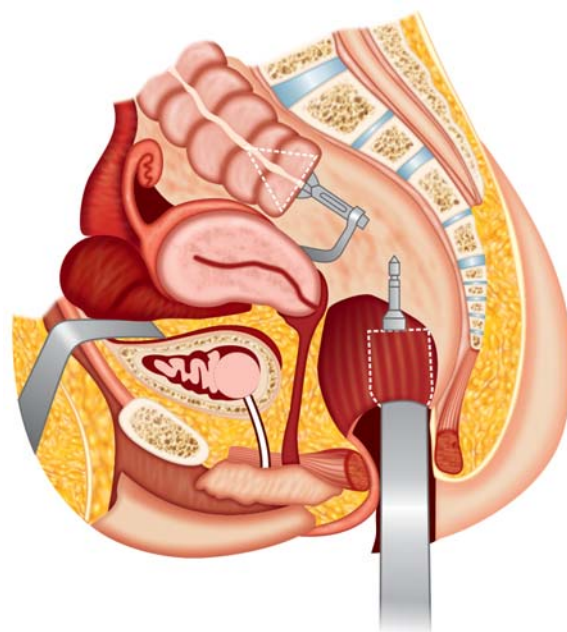


Fig. 2: Diagrammatic representation of surgical technique—mobilization and preparation of stump

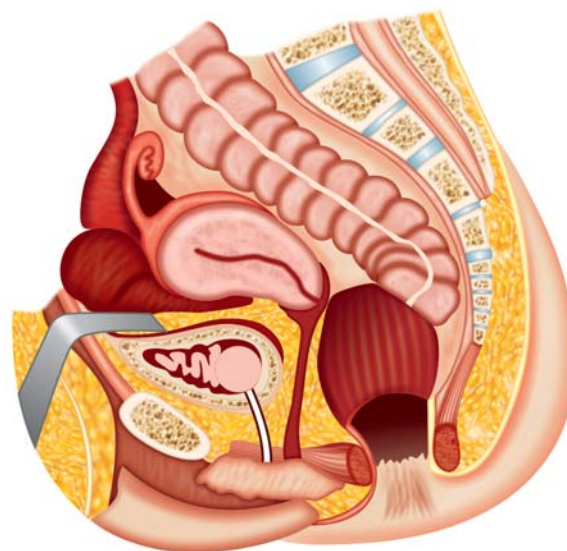


Fig. 3: Diagrammatic representation of surgical technique—completed stapled anastomosis

Timing of the reversal of Hartmann's operation is controversial. Waiting for maturation of scar tissue and adhesions allows the patient to recover from the underlying disorder. However, long intervals between primary surgery and closure may lead to atrophy of the distal stump. Actually, locating and manipulating the rectal stump is easier the earlier the procedure is done.¹⁰

The problem of identification arises when the rectal stump is short. Creation of a distal mucus fistula is the best way of identifying the distal stump but is not feasible in all cases. Tagging of the rectal stump with nonabsorbable sutures or to the sacrum has been found to be of variable help in identifying the rectal stump.^{11,12} Other maneuvers, such as packing the vagina or rectum and pushing the perineum cephalad can help in identifying the difficult rectal stump. Insertion of a lighted sigmoidoscope per rectum may also be helpful. We think it is important to be forewarned that a short rectal stump exists (using a per rectum contrast study) and thus look for it in the appropriate place. Packing the rectum tightly in both our patients also helped. If all these maneuvers prove to be unsuccessful, the anorectal stump can be accessed through the perineum, a field that is virgin in such patients.¹³

Following Hartmann's procedure, the rectal stump undergoes shrinkage, and changes of diversion colitis develop with time.¹⁴ The rectum has usually been closed resulting in fibrosis and distortion of the apex of the stump. It may thus be difficult to maneuver the circular stapler through the apex. Amputation of the apex results in further shortening of the rectal stump and may make it impossible to place a purse string suture in such a low stump. An alternative strategy is to bring the stapler out through the anterior wall of the rectum.¹¹ This would have involved separating the densely adherent vagina from the rectal stump with the fear of vaginal injury or an iatrogenic rectovaginal fistula. Separating the rectal stump from the sacrum was

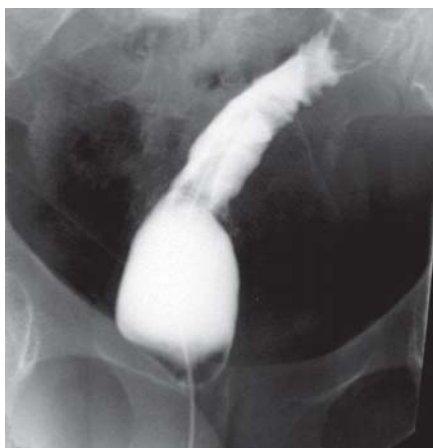


Fig. 4: Postoperative contrast study prior to stoma closure

safer and technically easier since this area had not been dissected earlier in our patients. This method of colorectal anastomosis also preserved whatever, length of rectal stump was available along with its reservoir function. Both patients enjoy a near normal stool frequency after surgery.

ACKNOWLEDGMENT

We deeply appreciate the help of Mr Piara Singh, Artist, in our institute for his help with the artwork.

REFERENCES

1. Desai DC, Brennan EJ Jr, Reilly JF, Smink RD Jr. The utility of the Hartmann procedure. *Am J Surg* 1998;175:152-54.
2. Schein M, Decker G. The Hartmann procedure. Extended indications in severe intra-abdominal infection. *Dis Colon Rectum* 1988;31:126-29.
3. Schmelzer TM, Mostafa G, Norton HJ, et al. Reversal of Hartmann's procedure: A high-risk operation? *Surgery* 2007; 142:598-607.
4. Pearce NW, Scott SD, Karran SJ. Timing and method of reversal of Hartmann's procedure. *Br J Surg* 1992;79:839-41.
5. Wigmore SJ, Duthie GS, Young IE, et al. Restoration of intestinal continuity following Hartmann's procedure: The Lothian experience 1987-1992. *Br J Surg* 1995;82:27-30.
6. Roe AM, Prabhu S, Ali A, et al. Reversal of Hartmann's procedure: Timing and operative technique. *Br J Surg* 1991;78: 1167-70.
7. Nugent KP, Daniels P, Stewart B, et al. Quality of life in stoma patients. *Dis Colon Rectum* 1999;42:1569-74.
8. Indian Council of Medical Research. *Illegal abortion in rural areas: A task force study*. New Delhi, India: ICMR 1989.
9. Jhobta RS, Attri AK, Jhobta A. Bowel injury following induced abortion. *Int J Gynaecol Obstet* 2007;96:24-27.
10. Roque-Castellano C, Marchena-Gomez J, Hemmersbach-Miller M, et al. Analysis of the factors related to the decision of restoring intestinal continuity after Hartmann's procedure. *Int J Colorectal Dis* 2007;22:1091-96.
11. Keck JO, Collopy BT, Ryan PJ, Fink R, Mackay JR, Woods RJ. Reversal of Hartmann's procedure: Effect of timing and technique on ease and safety. *Dis Colon Rectum* 1994;37:243-48.
12. Gervin AS, Fischer RP. Identification of the rectal pouch of Hartmann. *Surg Gynecol Obstet* 1987;164:176-78.
13. Abou-Zeid AA, Makki MT. Combined abdominal and perineal approach for delayed restoration of bowel continuity after low anterior resection in females. *Dis Colon Rectum* 2006;50: 544-47.
14. Roe AM, Brown C, Brodribb AJ. Changes in the defunctioned anorectum following Hartmann's operation. *Br J Surg* 1990;77: 1426-27.

ABOUT THE AUTHORS

Gurpreet Singh (Corresponding Author)

Professor, Department of General Surgery, Postgraduate Institute of Medical Education and Research, Chandigarh, India, e-mail: gsinghpgi@sify.com

Vikas Gupta

Additional Professor, Department of General Surgery, Postgraduate Institute of Medical Education and Research, Chandigarh, India