

Clinicopathological Conference Report—PM 25173

Granulomatous Amoebic Meningoencephalitis: A Diagnostic Dilemma

CPC Editor : Prof Nandita Kakkar
CPC Chairperson : Prof Vinay Sakhuja
Pathology Discussant : Prof BD Radotra
Clinical Discussant : Dr Manoj Kumar Goyal
Radiology Discussant : Dr Sameer Vyas
Clinician Incharge : Prof Vinay Sakhuja

This case (PM 25173) was discussed on 27th February 2013 as a staff clinicopathological exercise at Postgraduate Institute of Medical Education and Research (PGIMER), Chandigarh, India.

Clinical protocol and Case analysis, Dr Manoj Kumar Goyal, Assistant Professor, Department of Neurology, Postgraduate Institute of Medical Education and Research (PGIMER), Chandigarh, India.

CLINICAL PROTOCOL

An 18-year-old male presented with headache since 30 days, right upper limb weakness and slurring of speech since 20 days and altered sensorium since 5 days. The headache was holocranial, persistent throughout the day, continuous, severe and associated with vomiting. The right-sided hemiparesis was acute in onset and gradually progressive, started with slurring of speech and right upper limb weakness which progressed over 10 days to involve the right leg. He could not recognize his relatives, eat or speak. On general physical examination, he was drowsy (E4 M5 V1), pulse was 64/minute, BP: 114/70 mm Hg and respiratory rate was 24/min. Central nervous system (CNS) examination revealed neck rigidity, right UMN 7th nerve palsy, spasticity in all four limbs (right > left) and plantars were bilateral and equivocal. The hemoglobin was 16 gm%, TLC was 29×10^3 with 90% polymorphs and the platelets were normal. Blood biochemistry revealed a serum creatinine of 2.4 mg%, blood urea of 133 mg%, serum bilirubin of 1.3 mg%, OT: 829, PT: 587, alkaline phosphatase: 123, albumin: 2.5 gm% and globulin: 1.6 gm%. The CSF done outside revealed 27 cells (25 lymphocytes); glucose: 72; protein: 65; ADA: 2.17. The CSF done in PGI revealed 20 cells (all lymphocytes); glucose: 71; protein: 130; cryptococcal Ag negative, culture negative, TB-PCR negative. CT brain done revealed gyri in left parietal lobe to appear bulky and hyperdense forming a focal lesion measuring 3.1×2.9 cm with surrounding white matter edema and postcontrast enhancement with central hypodensity. This was effacing the ipsilateral lateral ventricle, causing a midline shift of 3 mm to the right side. A similar lesion was seen in right parafalcine right frontal lobe measuring 1.3×0.8 cm. Leptomeningeal enhancement was seen in left frontoparietal temporal region. The

impression was focal cerebritis with leptomeningitis in above described regions. MRI brain (Fig. 7) revealed multiple ill-defined heterogeneous intra-axial mass lesions seen in the left cerebellum, bilateral frontoparietal, left temporal and left occipital lobes. These lesions were appearing hypointense with faint hyperintensity within it on T1 and predominantly hyperintense on FLAIR/T2-weighted images. These lesions were showing blooming on SWI suggestive of hemorrhage within the lesions. On postcontrast scans, these lesions showed mild enhancement. Moderate perilesional white matter edema was seen around these lesions with lesion in left frontoparietal lobe producing mass effect seen as partial effacement of the left lateral ventricle with midline shift of about 5 mm. One of the mass is also involving the corpus callosum. A diagnosis of septic emboli/tubercular meningitis was considered. He was managed with vancomycin and ceftriaxone. He was on antitubercular treatment since 24th Dec 2012, which was continued. He was also given antiedema measures with steroids. However, he did not improve and had further worsening of sensorium and expired on 5th Jan 2013. The unit's diagnosis was multiple space occupying lesions abscesses with raised intracranial pressure (ICP).

CASE ANALYSIS

Thus, in nutshell, we have an 18 years old boy with 4 weeks history of headache and right faciobrachial weakness, with progression into altered sensorium and death (4th week into illness). There was no fever, seizures, visual or bulbar symptoms and there were no systemic complaints either. On examination, in addition to altered sensorium, he had neck rigidity, spasticity in all four limbs along with right-sided supranuclear 7th nerve palsy. With regards to clinical

approach, as is true in any neurological disorder, we have to answer three basic questions: (1) are we dealing primarily with a neurological disorder or with a systemic disease with neurological manifestations? (2) what is the anatomical localization? (3) what is the likely etiology?

As there were no systemic complaints, we are likely dealing with a primary neurological disorder. He had mild faciobrachial weakness (no plegia) and so damage is likely to be in cortex or subcortical white matter, bilateral as he has bilateral spasticity. The altered sensorium is likely secondary to diffuse cortical involvement and/or raised ICP which may also account for the headache. The differential diagnosis of conditions which present with bilateral multifocal disease process, with rapid progression to death is vast and includes: (1) demyelinating diseases (ADEM, acute hemorrhagic leukoencephalitis), (2) vascular (CNS angiitis/cerebral venous sinus thrombosis), (3) infectious (tubercular/fungal meningitis, parasitic—*Toxoplasma*, amoeba, pyogenic meningitis with arteritis, septic emboli, brucellosis, bartonella, etc.) and (4) neoplastic (metastases, lymphomas) disorders.

The cerebrospinal fluid (CSF) examination was noncontributory in this patient as it revealed only mild pleocytosis with raised protein which is nonspecific and barring pyogenic meningitis, these findings may be seen in all other disorders. The radiology, however, contributed a lot and salient features, which were noticed on MRI of brain, were multifocal brain lesions with significant mass effect, leptomeningeal and gyral enhancement and presence of diffusion restriction as well as hemorrhage within the lesion.

Both acute disseminated encephalomyelitis and acute hemorrhagic leukoencephalitis (AHLE) can have a fulminating onset and AHLE may be rapidly fatal. The CSF finding can be nonspecific in both conditions. However, MRI findings, such as distribution of lesions, presence of diffusion restriction even at 1 month of onset of illness and most importantly leptomeningeal and gyral pattern of enhancement, make these conditions unlikely in this patient. As far as multifocal CNS neoplasms are considered, presence of hemorrhage, gyral and leptomeningeal enhancement and location of lesion makes lymphoma unlikely, while diffusion restriction as well as enhancement pattern makes CNS metastases unlikely. Regarding vascular disorders, cerebral venous sinus thrombosis has been ruled out by normal MRI. Regarding CNS angiitis, clinical picture can be fulminant with diffuse cortical involvement, systemic symptoms may be absent, and CSF may reveal only mild pleocytosis and raised protein as seen in this patient. Furthermore, all MRI findings, like leptomeningeal and gyral enhancement, diffusion restriction, large lesions with

mass effect as well as intraparenchymal hemorrhage, have been described in CNS angiitis. However, in this patient, there was no evidence of peripheral nervous system involvement as well as no systemic complaints making an underlying connective tissue disorder/systemic vasculitis unlikely and primary CNS vasculitis is diagnosis of exclusion, as all other possible infectious etiologies for vasculitis (viral, bacterial, tubercular, etc.) have to be ruled out before considering this diagnosis. Moreover, infectious etiologies are much more common in our part of world as cause of CNS angiitis rather than the idiopathic variety.

Regarding infectious causes, pyogenic meningitis can be ruled out by absence of fever and CSF findings and septic emboli are unlikely for lack of systemic complaints and normal cardiac examination. This constellation of MRI findings has not yet been described in literature for brucellosis and bartonella, making these diagnoses very unlikely. With regards to tubercular meningitis, most of the findings on MRI can be explained, and rarely hemorrhage can also be seen though this is a very rare finding. CSF findings can be nonspecific and clinical course can be variable. Thus, this possibility needs to be considered though less likely in view of parenchymal hemorrhage. Regarding other etiologies, all these MRI findings can occur with fungal meningitis. In this patient, we have primarily parenchymal involvement which makes yeast like fungi unlikely which primarily cause meningitis. The fungi which can present with this picture include aspergillosis and mucormycosis and need to be considered strongly. Among these, aspergillosis is much more likely as there was no evidence of any paranasal sinus involvement as is common in case of mucormycosis. Finally, regarding parasitic disease, CNS toxoplasmosis can present in exactly the same manner and MRI may reveal large lesions with parenchymal hemorrhage. However, location of lesions as well as gyral and leptomeningeal pattern of enhancement makes this condition less likely. Regarding amoebic meningoencephalitis, it can present in exactly the same way without any systemic complaints. CSF findings in granulomatous amoebic meningoencephalitis can be exactly the same and MRI may reveal all the abnormalities seen in this patient—meningeal hyperemia, gyral enhancement, diffusion restriction, large tumor like lesions and presence of intralesional hemorrhage which is an important diagnostic criteria. Thus, this possibility needs to be considered very strongly. This patient died with 2 days of admission to our institute and thus brain biopsy could not be carried out which was planned. So, the most likely clinical diagnosis in this case is amoebic/fungal (*aspergillus*) meningoencephalitis.

OPEN HOUSE DISCUSSION

- *Senior Resident:* Well, this patient was very sick and stayed in hospital for only 2 days. There is a possibility of bacterial infection with patent foramen ovale. He did have involvement of liver/kidneys which cannot be explained by focal infection of the brain. Yes, amoebic meningoencephalitis is a very good possibility.
- *Dr S Jain:* We may consider fungal/amoebic infection but there is no history of swimming, diabetes mellitus or any immunosuppression. So, if it turns out to be this, then it is very unusual.

AUTOPSY PROTOCOL: PM 25173

Dr BD Radotra, Professor, Department of Histopathology, PGIMER, Chandigarh.

A partial autopsy limited to brain removal was performed on a thin built individual. The prosecutor noted that the brain was adherent to dura mater and was very soft to feel. The brain weighed 1,352 gm. The cerebral hemispheres were symmetric and the gyration was normal. The blood vessels of the circle of Willis were of medium caliber and did not reveal any atheroma or thrombosis. There was purulent meningeal exudate on frontoparietal convexities. Brain swelling with evidence of bilateral uncal and tonsillar herniations was present. On coronal slicing, multiple variable-sized hemorrhagic and necrotic lesions were seen which affected frontal and parietal lobes on both sides (Fig. 1). The largest lesion was noted in right anterior frontal lobe and measured about 6 cm in its maximum dimension. The left middle and inferior frontal gyri, left insular cortex, left superior temporal gyrus, right superior and middle frontal gyri, both cingulate gyri and right frontal central white matter were affected. The corpus callosum was also involved. The occipital lobes demonstrated necrotic lesions but to a lesser extent. The striate (visual) and peristriate cortices were affected on left side. The left cerebellum showed a similar necrotic lesion which measured about 1 × 1 cm (Fig. 2). The pons and medulla were spared. On histology, the leptomeninges showed exudate which contained large number of lymphocytes and macrophages admixed with neutrophils (Fig. 3). There was abundant karyorrhexis. Many leptomeningeal blood vessels showed acute necrotizing inflammation with thrombosis (Fig. 3). The cortical involvement was quite predominant compared to the white matter. There was angiocentric necrotizing inflammation. Perivascular spaces were found to contain large number of trophozoites (Fig. 4). A few cyst forms were identified among trophozoites. Granulomatous inflammation with giant cell reaction was also noted in the brain parenchyma (Fig. 5). Due to vascular thrombosis, the

adjacent cortical areas showed recent infarction (Fig. 6). The organisms were better identified by semi-thin sections. Since macrophages can be mistaken for trophozoites, a CD68 immunostaining (macrophage marker) was done which was negative, thereby further confirming that these are trophozoites. The brain tissue from lesions submitted for PCR did not demonstrate positive result for *Acanthamoeba* and hence it is ruled out. *Naegleria fowleri* has a very acute presentation and does not show any cysts or granulomatous inflammation. Most likely this infection is by *Balamuthia mandrillaris* due to the presence of cysts and the granulomatous inflammation that is seen along with. However, further characterization by IHC and PCR is required.

FINAL AUTOPSY DIAGNOSIS: PM 25173

Granulomatous amoebic meningoencephalitis possibly by *Balamuthia mandrillaris*.

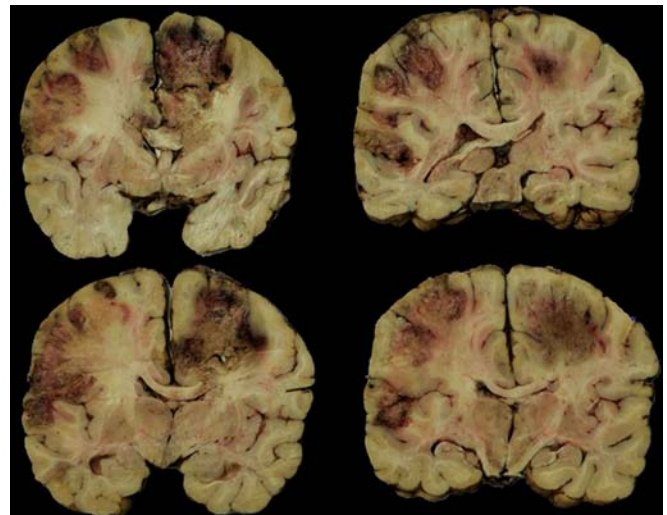


Fig. 1: Coronal slices of the brain with extensive hemorrhagic and necrotic lesions in both cerebral hemispheres

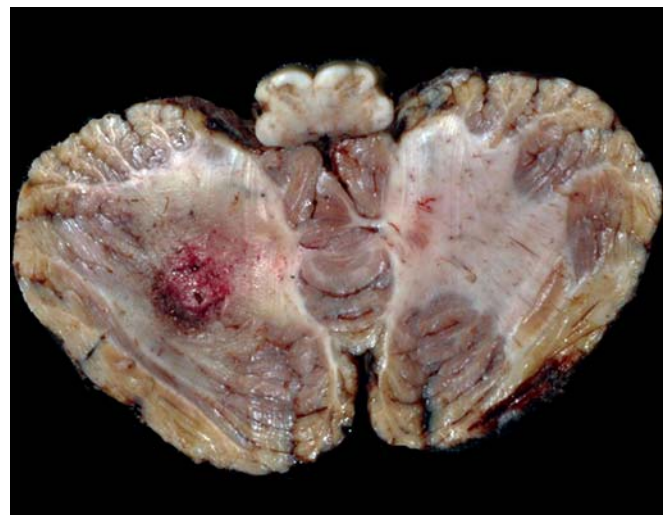


Fig. 2: Left cerebellar hemisphere shows a necrotic lesion affecting folia and white matter

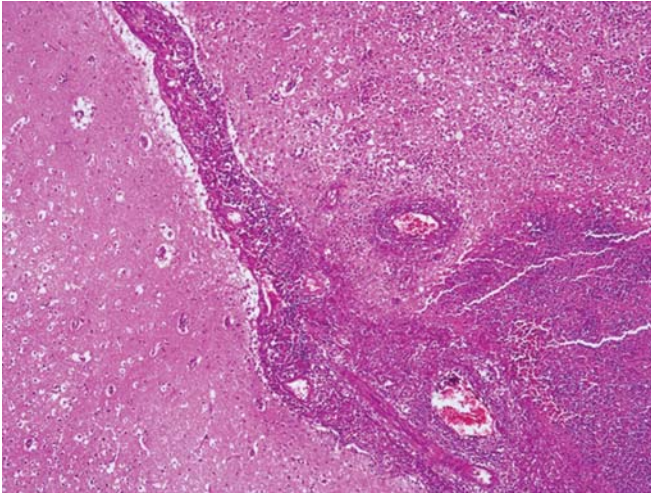


Fig. 3: Leptomeningeal exudate with vascular thrombosis

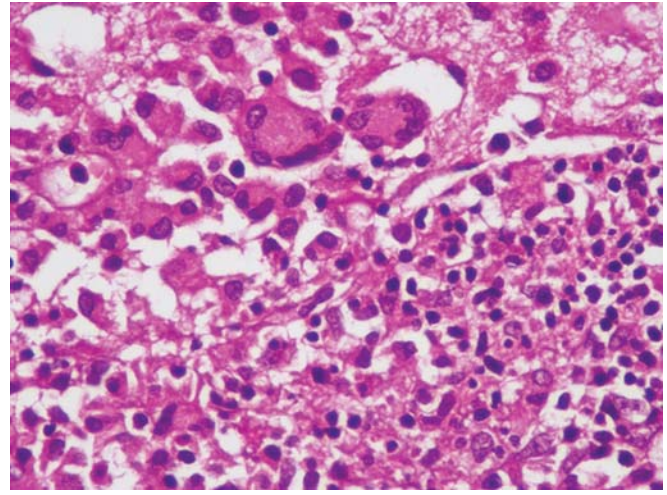


Fig. 5: Giant cell reaction in addition to mixed parenchymal inflammation

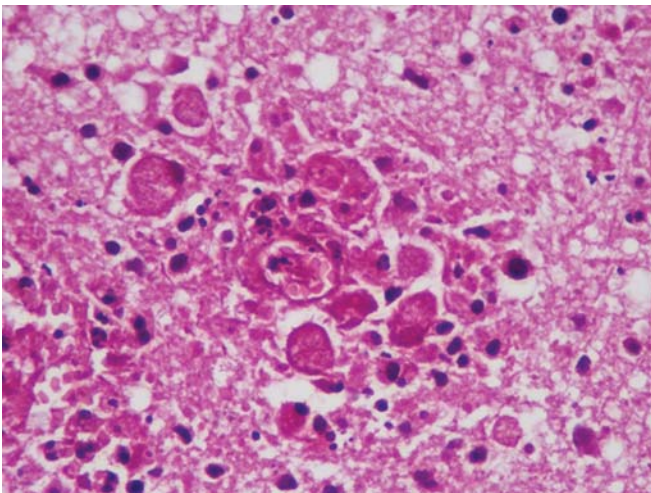


Fig. 4: Perivascular collections of amoebic trophozoites in the brain parenchyma

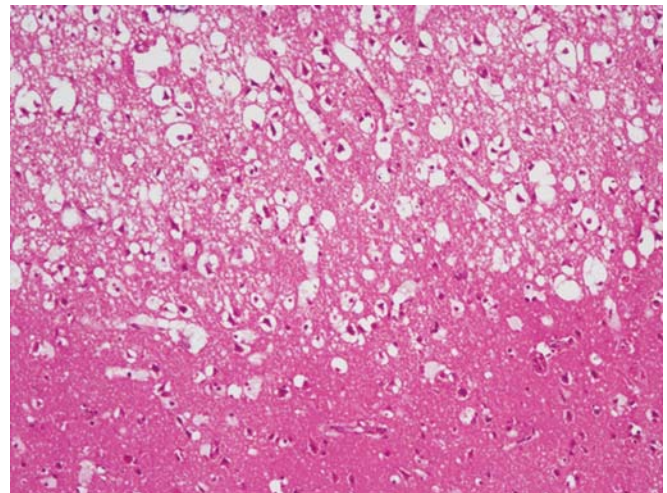


Fig. 6: Recent cerebral cortical infarction with edema. Lower half of photograph represents relatively spared area

OPEN HOUSE DISCUSSION

- *Dr Manish Modi:* There is a word of caution, that with such massive lesions in the brain producing this degree of mass effect as seen in this patient, the cause of death is uncal herniation due to the lumbar puncture that was done. If the radiology is not available, then a fundus examination is mandatory before resorting to a lumbar puncture. In case, the radiology is available and shows such a massive lesion, lumbar puncture should never be done. Or else, we will see the patient dying right in front of our eyes with cardiac and respiratory failure. In this patient, we should have gone in for a biopsy.
- *Senior Resident:* The patient died 2 days after the lumbar puncture was done.
- *Dr Dheeraj Khurana:* The diagnosis of PAM, in this case, surely could not have been made antemortem. What intrigued me is the hemorrhage. Is it due to venous involvement?

- *Dr BD Radotra:* Amoebic meningoencephalitis specifically involves the vessels leading to angiitis, rupture and hemorrhage. In this case, the meningeal arteries were clogged and showed vasculitis.
- *Dr ML Dubey:* We can rule out *N. fowleri* as this entity does not have the presence of cysts. *Balamuthia* and *Acanthamoeba* show the presence of cysts. PCR for *Acanthamoeba* is negative. So by exclusion, this is most likely to be *Balamuthia mandrillaris*.
- *Dr S Prabhakar:* Infection with *Naegleria* is very acute. No single drug is useful and hence we use a combination of rifampicin, erythromycin and two others for at least 1 month.
- *Dr BD Radotra:* Even on a brain biopsy, it is very difficult to make a diagnosis of amoebic infection, as we may get only necrosis or we may not hit the right area. To make a final diagnosis, we have to see the diagnostic trophozoites. But overall, a diagnosis can be

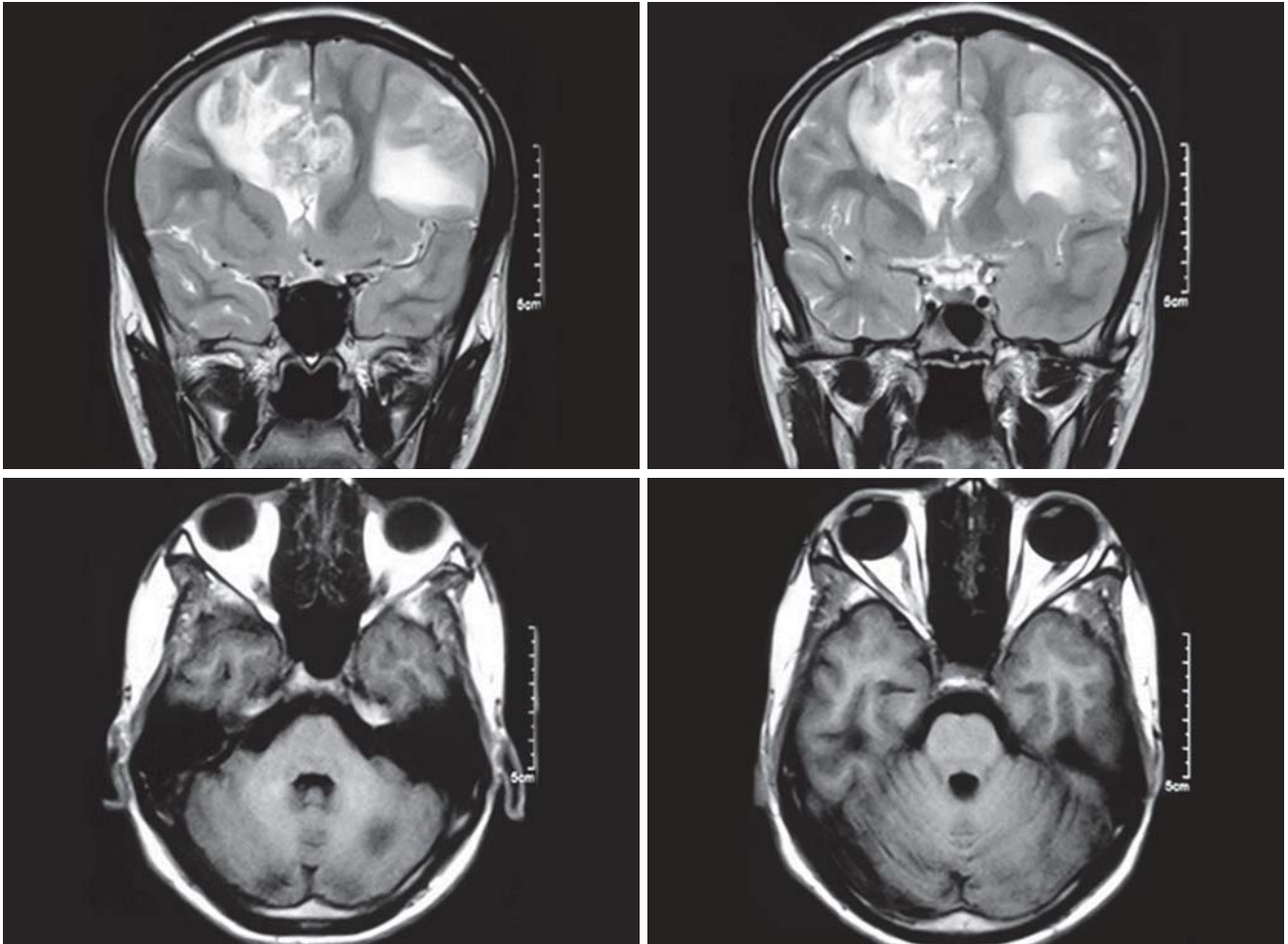


Fig. 7: Neuroimaging revealed multifocal lesions in bilateral cerebral hemisphere (upper panel) and left cerebellum (lower panel) with involvement of cortex and white matter

made by amalgamation of clinical, radiological, CSF picture/serology, PCR and biopsy. In this case, cysts were present and, as said before, it rules out infection by *Naegleria*. The important thing is the suspicion of amoebic infection and one must look for skin lesions and respiratory problems. Biopsy is surely the best diagnostic modality but has its limitations.

- *Dr V Sakhuja:* The point that Dr Modi made is very relevant. MRI can show us the anatomical localization of the lesions but does not give us the final diagnosis, which is however got by doing a biopsy. So, we need to go in for biopsies. The other alternative is to give a benefit of doubt and treat these patients or else we would lose all of them. This depends on the treating neurologist.
- *Dr M Goyal:* We were going to do a biopsy on this patient but unfortunately he died and did not give us enough time.
- *Dr N Khandelwal:* Gone are the days when only CT/MRI used to give the diagnosis. Now they are supplemented by perfusion/diffusion/SWI images to give more information. In this case, MR spectroscopy

could have ruled out lymphoma and malignancies and then we are left with infections. Many lesions seen on MRI are given ATT empirically and later they turn out to be nontubercular. We have to be cautious about labeling every ring/semi-ring lesion as a tubercular lesion and start off with ATT.

- *Dr V Sakhuja:* The series of amoebic meningo-encephalitis that was depicted had immunocompetent patients suffering from this disease. Are swimming pools a source of infection?
- *Dr BD Radotra:* Yes, *Acanthamoeba* affects the immunosuppressed but *Balamuthia* occurs in both, more so in the immunocompetent individuals. The organism lives in the soil and the portal of entry is the skin, respiratory tract and the mucous membranes.
- *Dr M Modi:* Yes, swimming pools too are a source of infection.
- *Dr Manoj Goyal:* There was a peculiar history of the patients' uncle splashing a glass of dirty water on his face. *Naegleria* is a universal commensal in the nose and spreads via the nasal cavity through the sinuses to the base of the brain. *Acanthamoeba* takes the

hematogenous route or begins with a keratoconjunctivitis.

- *Dr ML Dubey*: Naegleria is not a universal commensal in the nose although it comes through water. Acanthamoeba comes through skin lesions and so does Balamuthia.
- *Dr BD Radotra*: There is a case report in a 5 years old child who developed a skin nodule on the face and was treated with antibiotics, and 6 months later developed amoebic meningoencephalitis which was proven to be Balamuthia.
- *Dr V Sakhuja*: Well, thank you very much.

COMMENTARY

Amoebic meningoencephalitis, an extremely rare and sporadic CNS infection, is caused by free-living amoebae, specifically, *N. fowleri*, *Balamuthia mandrillaris*, as well as species of *Acanthamoeba* and *Sappinia*. Typically, *N. fowleri*¹⁻³ produces primary amoebic meningoencephalitis (PAM) which is clinically indistinguishable from acute bacterial meningitis. The other amoebae, i.e. *Balamuthia mandrillaris*⁴⁻¹⁰ and *Acanthamoeba* cause granulomatous amoebic encephalitis (GAE), which is a more subacute or chronic infection. The presentation of GAE can mimic a brain abscess, aseptic or chronic meningitis or CNS malignancy. These infections are nearly uniformly fatal and only a few survivors of PAM have been reported. A high degree of clinical suspicion is needed to correctly diagnose this infection. The high mortality rate is because of the difficulty of diagnosis and a poor to marginal response of patients to therapy. In most individuals with PAM or GAE, the diagnosis is made postmortem.

*N. fowleri*¹⁻³ is ubiquitous in most soils and propagates in warm, stagnant bodies of freshwater (typically during the summer months), and enters the CNS after insufflation of infected water by attaching itself to the olfactory nerve. It then migrates through the cribriform plate and into the olfactory bulbs of the forebrain where it multiplies itself greatly by feeding on nerve tissue. Children younger than 2 years frequently carry the organism asymptotically in their nose and throat, especially in warmer months and climates. PAM has an acute presentation (period of hours to 1-2 days) with high grade fever, headache, photophobia, stiff neck, nausea and vomiting. Additional symptoms include confusion, somnolence, seizures and coma. It commonly affects healthy children and young adults. This disease occurs more often during the warmer months of the year and in warmer climates. Patients with PAM may have a history of swimming, diving, bathing or playing in warm, generally stagnant and freshwater during the previous few

days to 2 weeks. Rarely, they may experience disordered smell or taste.

GAE apparently results from either acanthamoeba keratoconjunctivitis, via an uncommon phenomenon in which amoebae spread from the cornea to the CNS, or from the hematogenous spread of the ubiquitous organisms that cause GAE (*B. mandrillaris* and *Acanthamoeba* and *Sappinia* species) from primary inoculation sites in the lungs or skin (ulcer/nodule) to the CNS, where abscesses and focal granulomatous infections result. These infections often occur in hosts who are immunocompromised, but may also affect healthy hosts. GAE must be differentiated from brain abscess or tumor and aseptic or chronic meningitis. Typical symptoms of GAE include low-grade fever and focal neurologic signs, such as cranial nerve palsies, hemiplegia, ataxia, aphasia, diplopia and seizures. Patients with GAE may also exhibit behavioral changes, stiff neck, signs of increasing ICP, stupor or coma. Progression varies and, occasionally, patients survive for weeks or months. GAE affects individuals of all ages, although very young or very old persons may be more susceptible. It occurs throughout the year because the causative organisms are ubiquitous.

The index case had a subacute/chronic presentation with history of headache and right-sided hemiparesis since 1 month duration. He could not recognize his relatives, eat or speak. On CNS examination, he was drowsy (E4 M5 V1) and revealed neck rigidity, right UMN 7th nerve palsy, spasticity in all four limbs (right > left) and plantars were bilateral and equivocal. The MRI findings were consistent with those seen in granulomatous amoebic meningoencephalitis. Autopsy revealed features of granulomatous amoebic meningoencephalitis with the presence of trophozoites and cyst forms which can be seen either with *Balamuthia mandrillaris* or *Acanthamoeba*. As the PCR was negative for *Acanthamoeba*, so by exclusion this infection is by *Balamuthia mandrillaris*. Infection with *N. fowleri* is very acute and does not show the cyst forms or a granulomatous response.

REFERENCES

1. Kaushal V, Chhina DK, Ram S, Singh G, Kaushal RK, Kumar R. Primary amoebic meningoencephalitis due to *Naegleria fowleri*. *J Assoc Physicians India* 2008 Jun;56:459-462.
2. Vargas-Zepeda J, Gómez-Alcalá AV, Vásquez-Morales JA, Licea-Amaya L, De Jonckheere JF, Lares-Villa F. Successful treatment of *Naegleria fowleri* meningoencephalitis by using intravenous amphotericin B, fluconazole and rifampicin. *Arch Med Res* 2005 Jan-Feb;36(1):83-86.
3. Sugita Y, Fujii T, Hayashi I, Aoki T, Yokoyama T, Morimatsu M, Fukuma T, Takamiya Y. Primary amoebic meningoencephalitis due to *Naegleria fowleri*: an autopsy case in Japan. *Pathol Int* 1999 May;49(5):468-470.

4. Stidd DA, Root B, Weinand ME, Anton R. Granulomatous amoebic encephalitis caused by *Balamuthia mandrillaris* in an immunocompetent girl. *World Neurosurg* 2012 Dec;78(6):715-717.
5. Reed RP, Cooke-Yarborough CM, Jaquier AL, Grimwood K, Kemp AS, Su JC, Forsyth JR. Fatal granulomatous amoebic encephalitis caused by *Balamuthia mandrillaris*. *Med J Aust* 1997 Jul 21;167(2):82-84.
6. Pritzker AS, Kim BK, Agrawal D, Southern PM Jr, Pandya AG. Fatal granulomatous amoebic encephalitis caused by *Balamuthia mandrillaris* presenting as a skin lesion. *J Am Acad Dermatol* 2004 Feb;50 (2 Suppl):S38-S41.
7. Deol I, Robledo L, Meza A, Visvesvara GS, Andrews RJ. Encephalitis due to a free-living amoeba (*Balamuthia mandrillaris*): Case report with literature review. *Surg Neurol* 2000 Jun;53(6):611-616.
8. Riestra-Castaneda JM, Riestra-Castaneda R, Gonzalez-Garrido AA, Pena Moreno P, Martinez AJ, Visvesvara GS, Jardon Careaga F, Oropeza de Alba JL, Gonzalez Cornejo S. Granulomatous amoebic encephalitis due to *Balamuthia mandrillaris* (Leptomyxiidae): report of four cases from Mexico. *Am J Trop Med Hyg* 1997 Jun;56(6):603-607.
9. Matin A, Siddiqui R, Jayasekera S, Khan NA. Increasing importance of *Balamuthia mandrillaris*. *Clin Microbiol Rev* 2008 Jul;21(3):435-448.
10. Silva RA, Araújo Sde A, Avellar IF, Pittella JE, Oliveira JT, Christo PP. Granulomatous amoebic meningoencephalitis in an immunocompetent patient. *Arch Neurol* 2010 Dec;67(12):1516-1520.

ABOUT THE AUTHORS

Nandita Kakkar (Corresponding Author)

Professor, Department of Histopathology, Postgraduate Institute of Medical Education and Research, Chandigarh, India, e-mail: nandita_kakkar@yahoo.com

Vinay Sakhuja

Professor, Department of Nephrology, Postgraduate Institute of Medical Education and Research, Chandigarh, India

BD Radotra

Professor, Department of Histopathology, Postgraduate Institute of Medical Education and Research, Chandigarh, India

Manoj Kumar Goyal

Assistant Professor, Department of Neurology, Postgraduate Institute of Medical Education and Research, Chandigarh, India

Sameer Vyas

Assistant Professor, Department of Radiodiagnosis and Imaging Postgraduate Institute of Medical Education and Research Chandigarh, India