

Clinicopathological Conference Report—PM 26102

Gastric Signet Ring Cell Carcinoma presenting as Obstructive Uropathy: A Diagnostic Conundrum

Editor : Prof Nandita Kakkar¹
Chairperson : Prof Subhash C Varma²
Pathology Discussant : Dr Balan Louis Gaspar³
Clinical Discussant : Prof SK Singh⁴
Radiology Discussant : Dr Anupam Lal⁵
Clinician Incharge : Prof KL Gupta⁶

This case was discussed on 1st October 2014 as a staff clinicopathological exercise at Postgraduate Institute of Medical Education and Research (PGIMER), Chandigarh, India.

CLINICAL PROTOCOL: PROF SK SINGH

A 70-year-old gentleman, retired clerk and resident of Bihar presented with nausea, vomiting, giddiness, hesitancy and poor urine stream for 3 months. Loose stool, abdominal distension and altered sensorium were present since 10 days. The vomiting was 2 to 3 episodes per day, non-projectile, yellowish, non-foul smelling containing ingested food particles. There was no history of frequency, urgency, dysuria or hematuria. Patient was initially managed conservatively in a local hospital in Bihar as a case of gastroenteritis. His symptoms worsened and he developed altered sensorium. He was referred to another hospital, where his serum creatinine was found to be elevated from 0.9 to 3.6 mg/dl and bilateral hydronephrosis was detected on ultrasonography (USG). A detailed history of treatment was not available. He was then referred to the nephrology services

in postgraduate student (PGI). There was no history of diabetes, hypertension or tuberculosis. He was a known case of seizure disorder since childhood and was on regular sodium valproate treatment. The patient had skipped his medication for the previous 2 days. On examination, there was pallor, pedal edema and facial puffiness. Pulse rate was 96/min, BP was 100/70 mm Hg and respiratory rate of 18/min. Respiratory system examination revealed bilateral coarse crepitations. Central nervous system examination revealed a Glasgow coma scale of 15 no. neck stiffness or any focal neurological deficit. Examination of the abdomen revealed increased abdominal girth with free fluid. Cardiovascular system examination was within normal limits. Digital rectal examination revealed grade 1 prostatomegaly. Throughout the course of the hospital stay, polymorphonuclear leukocytosis was seen. Electrolytes were normal. Serum alkaline phosphatase was raised but the other liver function tests were normal. Ascitic fluid serum-ascites albumin gradient (SAAG) was 0.8 and adenosine deaminase (ADA) was 12. The cerebrospinal fluid (CSF) examination was within normal limits. Pleural fluid cytology was suspicious of malignancy. Serum PSA was 3.8 ng/mL. Abdominal fat pad was negative for amyloid. Serum protein electrophoresis did not reveal any M-band. Ultrasound revealed bilateral hydronephrosis with median lobe enlargement of prostate, normal liver and spleen. Contrast enhanced computer tomography (CECT) revealed multiple enlarged hilar lymph nodes, left pleural effusion with massive collapse and multiple sclerotic bony lesions. Non-contrast computerized tomography (NCCT) kidneys, ureters and bladder (KUB) showed globular kidneys with hyperdense contents within the left pelvicalyceal system suggestive of pyonephrosis/infected hydronephrosis. Patient was treated with antibiotics and his diarrhea improved

^{1,4}Professor, ^{2,6}Professor and Head
³Senior Resident, ⁵Associate Professor

^{1,3}Department of Histopathology, Postgraduate Institute of Medical Education and Research, Chandigarh, India

²Department of Internal Medicine, Postgraduate Institute of Medical Education and Research, Chandigarh, India

⁴Department of Urology, Postgraduate Institute of Medical Education and Research, Chandigarh, India

⁵Department of Radiodiagnosis, Postgraduate Institute of Medical Education and Research, Chandigarh, India

⁶Department of Nephrology, Postgraduate Institute of Medical Education and Research, Chandigarh, India

Corresponding Author: Nandita Kakkar, Professor, Department of Histopathology, Postgraduate Institute of Medical Education and Research, Chandigarh, India, e-mail: nandita_kakkar@yahoo.com

initially. However, his condition deteriorated and his urine output decreased with concomitant rise in serum creatinine. He developed sudden cardiac arrest after a bout of vomiting and expired. The unit's final diagnosis was disseminated malignancy. Primary with metastasis to bone, pleura and lungs; obstructive uropathy and rapidly progressive renal failure.

CASE ANALYSIS: PROF SK SINGH

In summary, this was an elderly male who had gastrointestinal tract symptoms in the form of vomiting and diarrhea as the initial manifestation followed by altered sensorium along with symptoms of lower urinary tract obstruction with prostatomegaly, bilateral hydronephrosis, raised serum creatinine, solitary lung lesion, malignant pleural effusion with sclerotic bony metastasis, raised alkaline phosphatase, normal gamma glutamyl transferase, and neutrophilic leukocytosis. This case can be dissected out by discussing the following key clinical manifestations.¹ Bilateral hydronephrosis can be due to infravesical outflow obstruction *viz.* stricture urethra, prostatomegaly, and bladder dysfunction. Stricture urethra was unlikely as there was no difficulty in inserting the catheter. The most likely etiology in the index case would be either

- Carcinoma prostate
- Bladder tumor resulting in obstruction
- Extraneous pelvic malignancy
- Non-malignant process, such as retroperitoneal fibrosis resulting in secondary involvement of urinary bladder or prostate.

The digital rectal examination was normal in this patient but ultrasonographically enlargement of the median lobe of prostate was noted. The prostate-specific antigen (PSA) levels were within normal limits. All these would point toward benign enlargement of prostate. The odd feature was persistence of hydronephrosis despite catheterization, rising serum creatinine levels and sclerotic bony lesions. Hence, carcinoma of prostate was still on the cards. Normal PSA levels can be seen in poorly differentiated carcinoma and neuroendocrine carcinoma of prostate. An entity called prostatic adenocarcinoma with lung metastasis (PALM) is described in the literature where digital rectal examination can be normal (~40%). Sodium valproate therapy can lead to osteopenia but not osteosclerosis. Hence, osteosclerotic lesions with concomitant raised alkaline phosphatase, normal gamma glutamyl transferase, points toward a bone pathology which is likely to be secondary to metastasis. The next etiological probability that can be entertained would be a bronchial carcinoid. The points that would favor this would be solitary lung lesion, malignant effusion, osteosclerotic lesions

and gastrointestinal tract symptoms. The odd feature for this was the response of this patient to initial trial of antibiotics. Also, the possibility of foregut carcinoid was also likely because the patient had bilious vomiting. The lung lesion, malignant effusion and osteosclerotic lesions would have been secondary to metastasis. The cause of altered sensorium and vomiting needs special mention as uremic encephalopathy and paraneoplastic syndromes can be the cofactors. The gastrointestinal symptoms were of long duration and hence uremic encephalopathy as the sole cause is highly improbable. Paraneoplastic syndrome was still a probability. Pyelonephritis or pyonephrosis were suggested in the radiological investigations as the kidneys were globular, with debris in the pelvicalyceal system in addition to persisting polymorphonuclear leukocytosis. Odd feature was that the urine culture did not reveal any bacterial growth of significance. Also fungus, as a cause of pyelonephritis cannot be entirely ruled out. The ascites was exudative with WBC count of 220 (predominantly polymorphs) and admixture of RBCs. Infective etiology as well as malignancy needs to be considered. Per-se, carcinoma of prostate with peritoneal seeding is uncommon and the reports are only anecdotal. Gastrointestinal malignancy is a possibility. Hence, the most likely diagnosis in this would be metastatic carcinoma the likely primaries being prostate, lung and foregut; pyelonephritis leading to urosepsis; terminal event being aspiration pneumonia.

OPEN HOUSE DISCUSSION

- *Dr Manish Rathi:* IgG4 related disease should be considered, as this can present with sclerotic manifestations.
- *Dr Rakesh Kapoor:* Carcinoma of lung especially the mucinous adenocarcinoma with paraneoplastic manifestations is likely. Since multiple lymph nodes were enlarged, lymphoma cannot be excluded.
- *Dr Pankaj Mallhotra:* Non-hematolymphoid malignancy is most likely in this case. Lymphoma is a remote possibility.
- *Dr Gaurav Prakash:* The most likely diagnosis in this case would be a malignant neuroendocrine tumor, because the hydronephrosis did not improve after catheterization and neuroendocrine tumors are known to be associated with retroperitoneal fibrosis.
- *Dr Subhash C Varma:* Generally, paraneoplastic manifestations of carcinoid would be seen after liver metastasis and this patient did not have liver metastasis.
- *Dr GR Verma:* This patient primarily had gastrointestinal symptoms where he started with nausea and vomiting followed by diarrhea. The primary appears to be from the small bowel rather than large bowel

as there was no increase in mucus or blood in the stools. The possibility would be an adenocarcinoma or lymphoma rather than neuroendocrine tumor or primary prostate carcinoma.

- *Dr SK Sinha*: Rather than localizing the primary to be from small gut, pancreatic carcinoma and neuroendocrine tumor need to be considered as well.
- *Dr Anupam Lal*: Neuroendocrine tumors are hypervascular and can be entirely missed on non-contrast CT, as well as portal venous phase CT and can be picked only on arterial phase CT.
- *Dr Radhika Srinivasan*: The cytology findings rule out a lymphoma and carcinoma is more likely.
- *Dr Santosh Kumar*: Transitional cell carcinoma of prostatic urethra should also be considered.
- *Dr SK Singh*: Patient did not have hematuria and transitional cell carcinoma produces both osteosclerotic as well as osteolytic lesions. Clinically, this was not likely.

PATHOLOGY PROTOCOL: PM 26102 DR BALAN LOUIS GASPARD

A complete autopsy was performed in this well built individual. There was bilateral pitting pedal edema with ascitis, pleural and pericardial effusion. The esophagus was grossly and microscopically normal. The stomach was uniformly thickened giving a leather-bottle feel. The gastric mucosa showed four ulcers, two in the lesser curvature and one each in the greater curvature and pyloric antrum. The largest ulcer was 4 cm in maximum dimension. All the ulcers were flat and merged imperceptibly with the adjacent mucosa (Fig. 1A). The cut-surface showed full thickness involvement of the wall. All the draining lymph nodes around the stomach were enlarged and the cut-surface showed metastatic tumor deposits. Microscopically, the sections from the ulcers revealed ulcero-infiltrative tumor involving all the layers (Figs 1B to D) with concomitant deposits in the greater, lesser omentum along with lymph node metastasis. The tumor cells exhibited marked nuclear pleomorphism, but majority had abundant mucin filled cytoplasm pushing the nucleus to the periphery, thereby resulting in the classical 'signet-ring' appearance (Fig. 2A). Extensive lymphovascular embolized. The intracytoplasmic mucin was demonstrable with Alcian blue stain (Fig. 2B). Immunostains for PanCK and CK7 (Figs 2C and D) were positive while E-cadherin was negative (Fig. 2E). Hence the overall features were those of signet-ring cell carcinoma. The small and large intestines revealed uniformly thickened wall, but the mucosa did not reveal any ulcers. Microscopically, infiltration of the wall by signet ring cells was seen. The prostate was

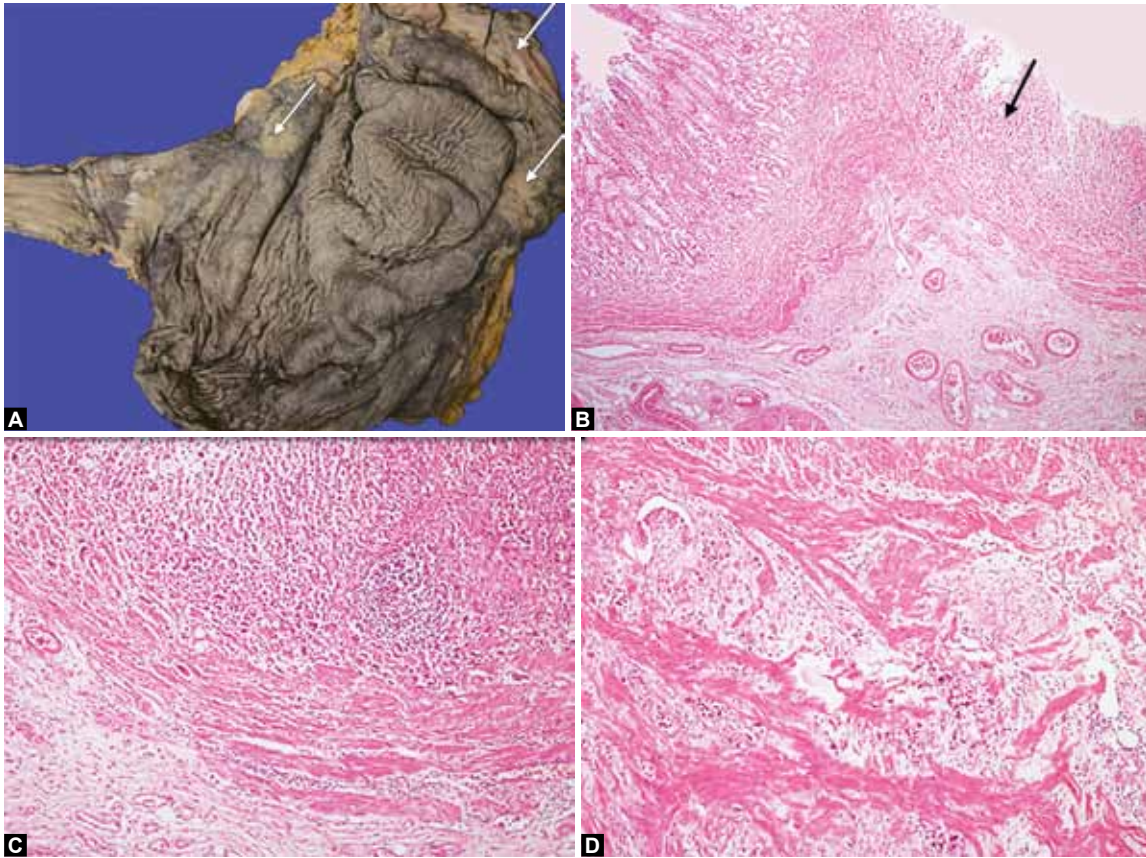
bulky and no focal lesions were identified; microscopically there was adenoleiomyomatous hyperplasia (Fig. 3D). External surface and mucosa of urinary bladder were within normal limits. The wall was thickened and perivesical fat was firmly adherent. Microscopic sections from the urinary bladder revealed a normal mucosa (Fig. 3A) but the detrusor muscle and perivesical fat showed infiltration by tumor cells (Figs 3B and C). The malignant cells were seen as a single cell infiltrate and were prominently seen within the lymphatics. The capsular aspect and cut surface of both kidneys was dull with indistinct cortico-medullary junction. The pelvicalyceal system and ureters were dilated. Microscopically, the medulla of the kidney showed infiltration by tumor cells, predominantly as a single cell infiltrate in the interstitium (Fig. 4A) and also within the lymphatics, accompanied by marked desmoplasia. Bone showed grossly visible grey-white tumor deposits 0.4 to 1 cm diameter. Microscopically, signet ring cell infiltrate with desmoplastic reaction was noted (Fig. 4B). Both the lungs were heavy and together weighed 1080 gm. The pleural aspect was dull. Cut section showed randomly distributed, patchy areas of consolidation and multiple nodules ranging in size from 0.4 to 4 cm diameter. The largest nodule was seen in the middle lobe of the right lung. Most of these lesions were better felt than seen. No thrombus was seen within the pulmonary arteries. Microscopic sections from the lungs revealed multiple, well circumscribed tumor deposits with extensive lymphatic involvement. The tumor cells within the nodules were highly discohesive, were alcian blue positive, CK7 positive (Fig. 4C) and CK20 negative. Areas of bronchopneumonia and intra-alveolar hemorrhage were also seen. No fungal profiles were noted, however incidental osseous metaplasia was observed. Hilar lymph nodes were enlarged and microscopically revealed infiltration by tumor cells, which showed similar features as in the lungs. Granulomatous inflammation was also noted in the hilar lymph nodes, but stains for AFB and PAS were negative. The heart showed fibrinous tags were seen on the epicardial surface. Grossly, all the chambers, valves and great vessels were within normal limits. Microscopically, however the epicardial surface revealed tumor deposits.

The adrenal and testes were grossly within normal limits, whereas microscopically metastasis was seen. The brain was grossly within normal limits. Microscopically, leptomeningeal metastasis was seen (Fig. 4D). The liver, spleen and pancreas did not show any metastasis.

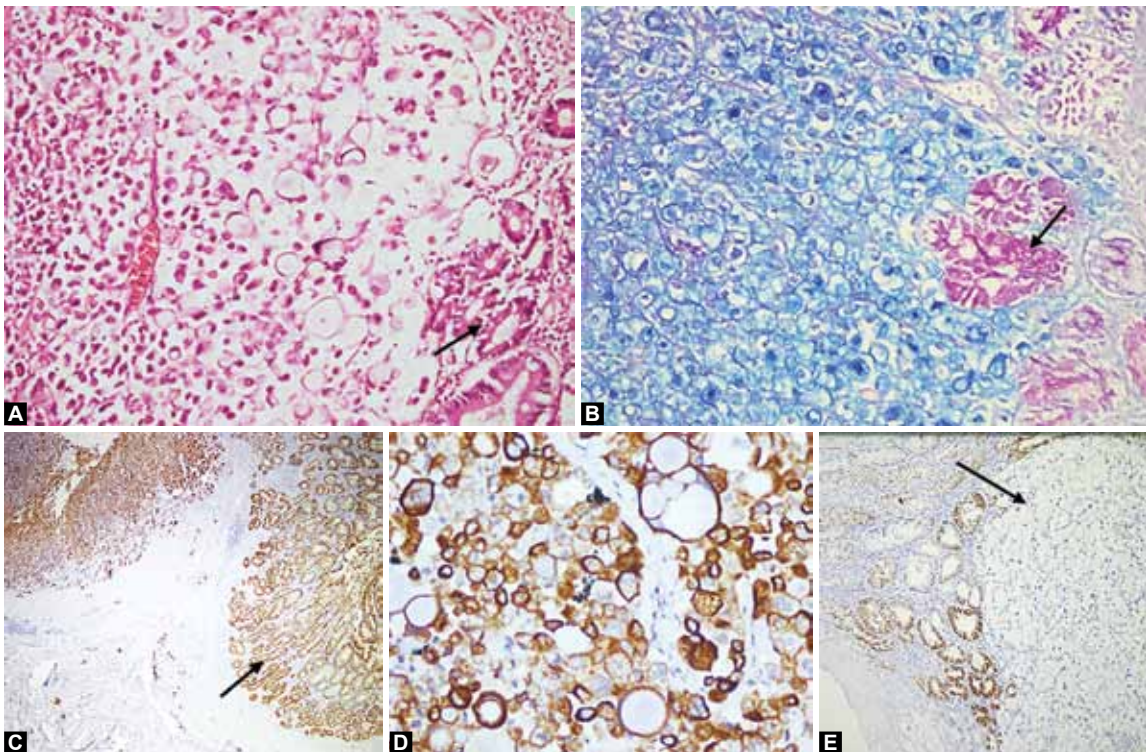
FINAL AUTOPSY DIAGNOSIS: PM-26102

Signet ring cell carcinoma of stomach with contiguous spread to the small as well as large intestine and

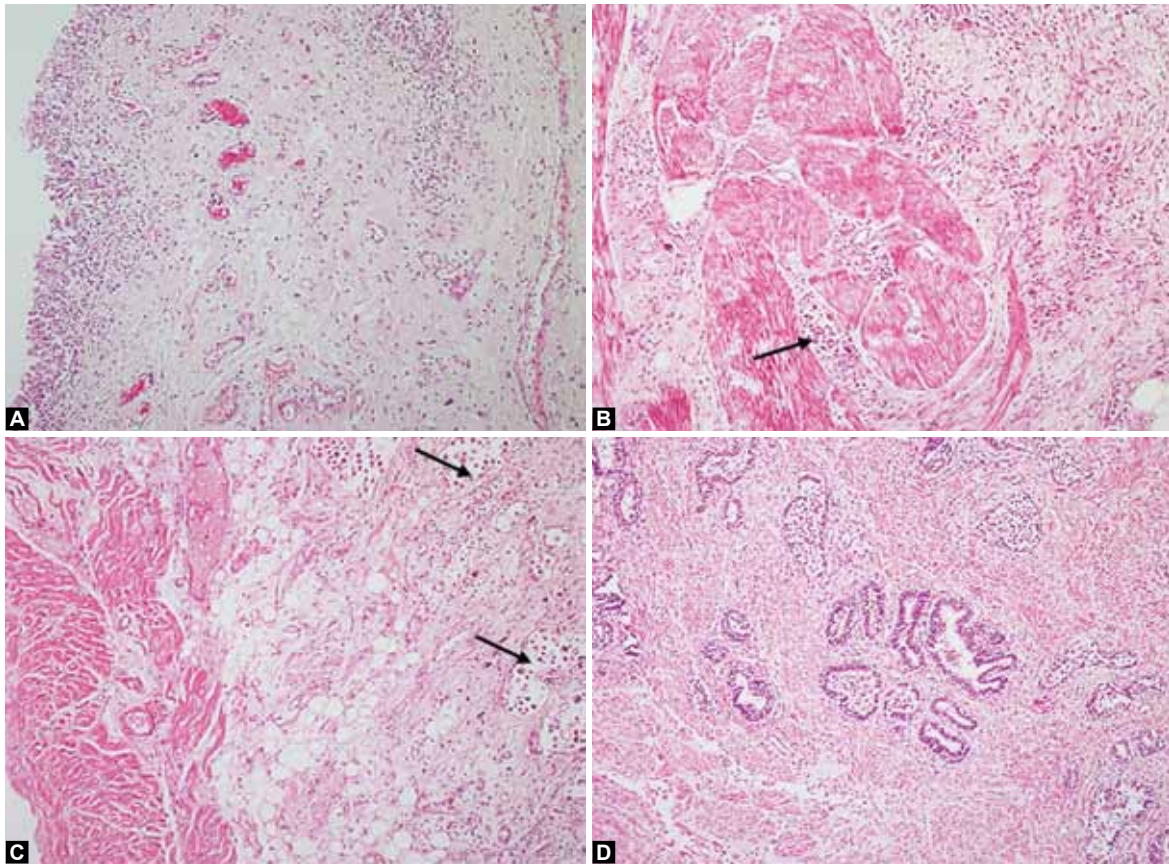




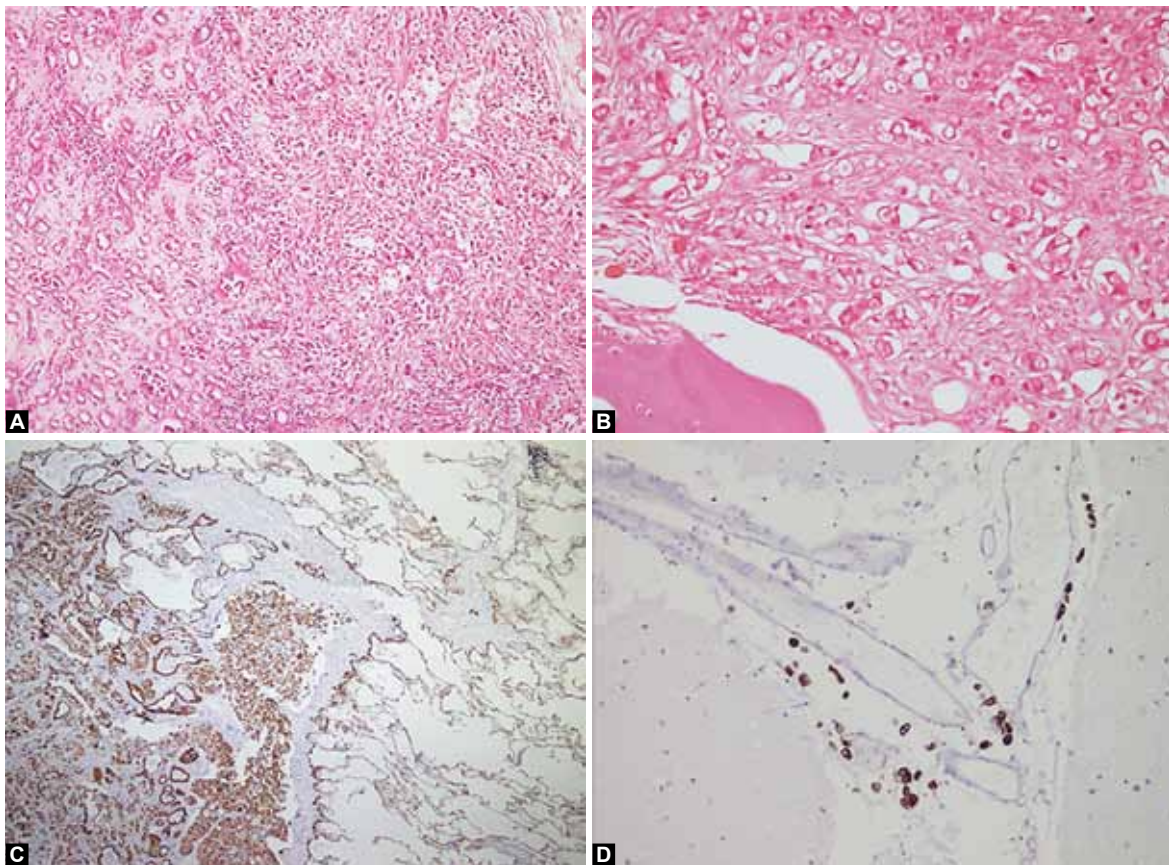
Figs 1A to D: (A) Stomach was uniformly thickened giving a leather-bottle feel with mucosal ulcers (white arrows), (B) Normal mucosa (left) compared to the frankly malignant area (arrow), (C) Infiltration by signet ring cells into the muscularis mucosae and (D) Infiltration into muscularis propria



Figs 2A to E: (A) Signet ring cells in H&E stain with adjacent normal mucosa (arrow), (B) Alcian blue-PAS stain wherein the signet ring cells are highlighted by Alcian blue and gastric mucosa appears magenta in PAS (arrow), (C) Pan cytokeratin immunostain highlighting both the normal mucosa (arrow) as well as the tumor, (D) CK7 immunostain positivity in tumor cells and (E) E-cadherin immunostain shows loss of staining in the invasive tumor area (arrow) and gastric mucosa acts as positive control



Figs 3A to D: (A) Normal bladder mucosa, (B) Infiltration of the detrusor by signet ring cells (black arrow), (C) Infiltration of the perivesical fat by signet ring cells (black arrows) and (D) Prostate shows glandular and stroma hyperplasia



Figs 4A to D: Infiltration by signet ring cells in (A) renal medulla and (B) bone, (C) CK7 immunostain to highlight pulmonary and (D) meningeal infiltration

metastasis to regional lymph nodes, urinary bladder, kidneys, lungs, pericardium, bones, adrenals, testes and leptomeninges.

OPEN HOUSE DISCUSSION

- *Prof Dheeraj Gupta:* The granulomas in the mediastinal lymph nodes may be sarcoid like which are seen in malignancies.
- *Dr Balan Louis:* They can be due to tumor antigens or due to tuberculosis.
- *Prof GR Verma:* Endoscopy should have been done in this patient. CECT was contraindicated but MRI could have been done.
- *Senior Resident:* The bony lesions could have been sampled antemortem which would have clinched the diagnosis.
- *Prof Subhash C Varma:* In a situation where there is a disseminated malignancy, whether the diagnosis of primary site would help or not needs to be answered. This is a second personal encounter with a gastric carcinoma with very severe fibrosis.
- *Dr Gaurav Prakash:* Classical case of carcinoma of unknown primary and the PET- scan is the investigation of choice.
- *Prof Ganga Ram Verma:* Clinically, this was a classical case of signet-ring cell adenocarcinoma and not a neuroendocrine carcinoma because neuroendocrine carcinoma does not disseminate as this patient had. They are slow growing tumors and patients survival is in years despite distant metastasis. Here the patient has succumbed to the illness within months. [18F]-fluorodeoxyglucose positron emission tomography (FDG-PET) has lots of false positive results and not the modality of choice to search for primary once the disease is disseminated. Adenocarcinoma is a pitfall as it has poor uptake in FDG-PET and can be missed.
- *Prof Virendra Singh:* Positron emission tomography-computed tomography (PET-CT) should not be the first choice in this case. The investigations should have been stool for occult blood followed by endoscopy and then PET-CT.
- *Prof Rakesh Kapoor:* Odd features difficult to explain in autopsy are non-involvement of liver despite dissemination to multiple organs and non-involvement of supraclavicular lymph node.
- *Prof Subhash C Varma:* That is clinical medicine. Somehow, somewhere, the diseases do not follow the rules, we have made and this happens very frequently.
- *Dr SK Sinha:* This patient had low (SAAG) ascites which could be due to malignancy, pancreas related or tubercular. Malignancy was on top of the list. Causes of malignant ascites are carcinoma stomach, colon and

pancreas. In females ovarian carcinomas in addition to the above. If this patient was worked up as a case of low SAAG ascites the possibilities could have been narrowed down. Tumor markers were also warranted in this case. Whether it matters to find the primary if the patient has malignant ascites. Yes it does matter to know whether it is lymphomatous or non-lymphomatous malignancy and if non-lymphomatous whether it is ovarian or non-ovarian. CA125 would have also helped.

- *Prof Radhika Srinivasan:* Immunohistochemistry can be performed from the cell blocks of pleural fluid and can narrow down the likely primaries.

COMMENTARY

Cancer of unknown primary site (CUP) is defined by the presence of a metastatic cancer without a known primary site of origin, despite a standardized diagnostic workup and accounts for 3 to 5% of all malignant epithelial tumors.¹ When lymphoma, leukemia, melanoma, germ cell tumor and sarcoma are excluded the terminology 'carcinoma of unknown primary' is preferred. Among the carcinomas of unknown primary 90% are adenocarcinomas or poorly differentiated carcinomas, 5% are squamous cell carcinomas and 5% are neuroendocrine carcinomas.² The median age for occurrence is around 60 years, with a slight male preponderance. Gastric carcinoma is the fourth most common cancer and the second most common cause of cancer related deaths worldwide.³ Signet ring cell carcinoma is a subtype of gastric adenocarcinoma which has a dismal outcome. When it occurs at the antropyloric region, it has the propensity to infiltrate the duodenum with serosal involvement. The carcinoma tends to have prominent lymphovascular invasion and lymph node metastasis.

Primary gastric signet ring cell carcinoma presenting as obstructive uropathy and renal failure is extremely uncommon and only a few reports are available in the literature.^{4,5} The probable reason for this presentation in our case would be due to detrusor muscle infiltration with concomitant adenoleiomyomatous hyperplasia of prostate. Classification of CUP into several clinicopathological subsets according to age, sex, histopathology, clinical presentation, and organ or site involvement helps the oncologists to investigate and plan for appropriate therapeutic management. In the cases lacking antemortem diagnosis, autopsy plays a vital role in the pathophysiology, diagnosis and natural history of the disease as is beautifully illustrated in the index case. Unfortunately, autopsy rates have been declining even in countries like the USA and Europe with the advancement of molecular techniques.⁶

REFERENCES

1. Pavlidis N, Fizazi K. Cancer of unknown primary. *Crit Rev Oncol Hematol* 2009;69(3):271-280.
2. Greco FA, Hainsworth JD. Cancer of unknown primary site, in: DeVita VTJ, Lawrence TS, Rosenberg SA, editors, *cancer: principles and practice of oncology* 2008;2363-2387, Lippincott Philadelphia, PA.
3. Ferlay J, Shin HR, Bray F, et al. Estimates of worldwide burden of cancer in 2008: Globocan 2008. *Int J Cancer* 2010;127(12):2893-2917.
4. Rosenblum H, Bar-Dayan Y, Dovrish Z, et al. The endless differential diagnosis of acute obstructive renal failure: unusual challenges for the sharp-sighted clinician. *Isr Med Assoc J* 2010;12(5):280-282.
5. Case records of the Massachusetts General Hospital. Weekly clinicopathological exercises. Case 10-1999. A 53-year-old man with acute renal failure, cortical blindness, and respiratory distress. *N Engl J Med* 1999;340(14):1099-1106.
6. Pentheroudakis G, Golfi Nopoulos V, Pavlidis N. Switching benchmarks in cancer of unknown primary: from autopsy to microarray. *Eur J Cancer* 2007;43:2026-2036.