

# Sutureless Vitrectomy for Repositioning of in-the-Bag Single Piece Acrylic Dislocated Intraocular Lens

<sup>1</sup>Ramandeep Singh, <sup>2</sup>Swapnil Madhukar Parchand, <sup>3</sup>Rishiraj Singh, <sup>4</sup>Neha Kumari

## ABSTRACT

We report a successful outcome in a case of dropped in-the-bag single piece intraocular lens (IOL), which was retrieved and refixated to sclera using 23-gauge transconjunctival sutureless vitrectomy (TSV). This technique of scleral refixation of same IOL using sutureless vitrectomy shows the versatility of the 23-gauge TSV in managing the difficult and cumbersome situations like above.

**Keywords:** 23-gauge transconjunctival sutureless vitrectomy, Dislocated intraocular lens, Dropped IOL, In-the-bag dislocated IOL, Sutureless vitrectomy.

**How to cite this article:** Singh R, Parchand SM, Singh R, Kumari N. Sutureless Vitrectomy for Repositioning of in-the-Bag Single Piece Acrylic Dislocated Intraocular Lens. *J Postgrad Med Edu Res* 2016;50(1):28-29.

**Source of support:** Nil

**Conflict of interest:** None

## INTRODUCTION

Late in-the-bag intraocular lens (IOL) dislocation occurs due to progressive zonular dehiscence in various conditions like pseudoexfoliation, etc.<sup>1</sup> Management options include 20-gauge pars plana vitrectomy (PPV) and removal of the capsular bag-IOL complex through a limbal wound followed by either exchange with an anterior chamber IOL, exchange with new scleral fixated posterior chamber IOL, or repositioning of the original IOL with scleral fixation sutures.<sup>2</sup> Since its introduction, sutureless vitrectomy has gained popularity over conventional PPV.<sup>3</sup> Kumar et al described sutureless 20-gauge PPV for managing the dislocated IOL with inadequate capsular support using tucking of IOL haptic into intralaminar scleral tunnel.<sup>4</sup> Lopez-Guajardo et al described the technique of scleral fixation of dislocated IOL through 23-gauge vitrectomy cannulas using polypropylene sutures in eyes with inadequate capsular

support.<sup>5</sup> These two studies talk about scleral fixation of polymethylmethacrylate (PMMA) and 3 piece acrylic IOLs. We did not come across any study describing refixation of in-the-bag single piece acrylic dislocated IOL using sutureless vitrectomy.

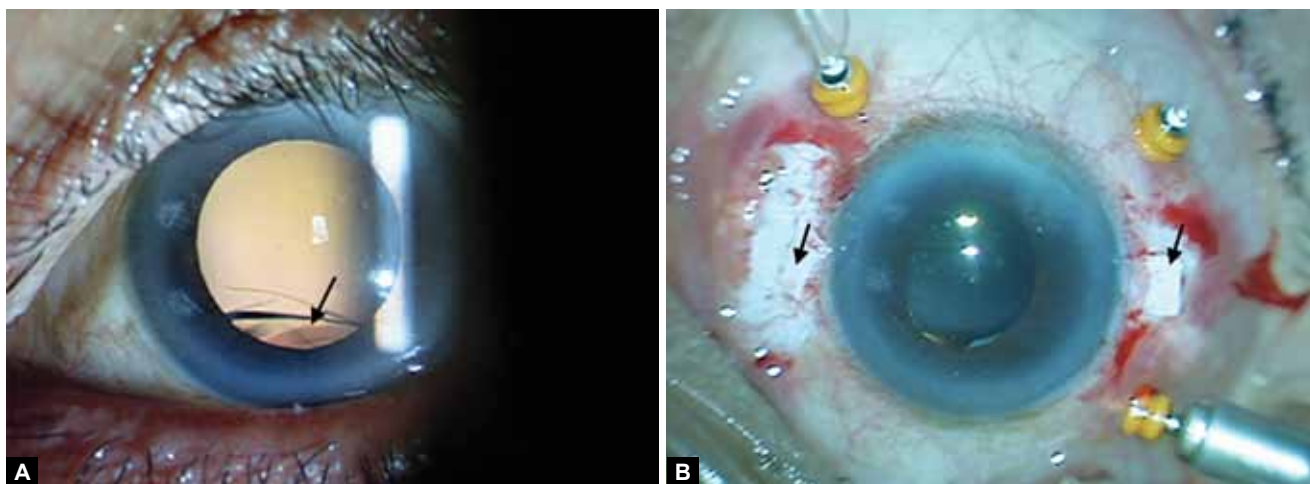
## CASE REPORT

Our patient was a 60-year-old male, who presented with sudden loss of vision in the left eye (OS). He underwent uneventful phacoemulsification with posterior chamber IOL (single piece acrylic lens) implantation in OS for nuclear cataract associated with pseudoexfoliation syndrome 3 years back. On examination, his best corrected visual acuity (BCVA) was 20/30 with aphakic correction in OS. Left eye had aphakia with in-the-bag dislocated IOL (Fig. 1A). Examination of OD was unremarkable. He was planned for 23-gauge transconjunctival sutureless PPV with scleral fixation of the same IOL after informed consent. Partial thickness rectangular scleral flaps were made along the horizontal meridians after doing localized conjunctival peritomy. 23-gauge cannulas were placed in the superotemporal, superonasal and inferotemporal quadrants. Additional anterior non-cannulated sclerotomies were made under the scleral flaps at 1.5 mm from the limbus. Intraocular lens was brought up to the anterior vitreous with end gripping intraocular forceps after releasing it from the vitreous. Localized trimming of the capsule was done at the edge of the haptics with the 23-gauge vitreous cutter to set it free. Another end gripping intraocular forceps was inserted through the anterior sclerotomy to engage edge of the one haptic of the dislocated IOL for temporary externalization through the sclerotomy. A double armed 10-0 polypropylene suture was used to tie a secured knot at the center of the explanted haptic. The same procedure was repeated for other haptic. Then the explanted haptics with the tied sutures were dialled back inside through the corresponding anterior sclerotomies into the vitreous cavity. The external needles were used to anchor it to the sclera (Fig. 1B). Scleral flaps and conjunctiva were closed with fibrin glue. Pars plana vitrectomy was completed and cannulas were removed. Intraoperative and postoperative period was uneventful. We especially looked for uveitis-glaucoma-hyphema

<sup>1</sup>Assistant Professor, <sup>2-4</sup>Senior Resident

<sup>1-4</sup>Department of Ophthalmology, Postgraduate Institute of Medical Education and Research, Chandigarh, India

**Corresponding Author:** Ramandeep Singh, Assistant Professor Department of Ophthalmology, Postgraduate Institute of Medical Education and Research, Chandigarh, India, e-mail: [mankoo95@yahoo.com](mailto:mankoo95@yahoo.com)



**Figs 1A and B:** (A) Preoperative, anterior segment photograph of the left eye showing dilated pupil and in-the-bag dislocated intraocular lens lying inferiorly (arrow) and (B) intraoperative photograph of the left eye showing well centered intraocular lens with sclerotomy flaps in horizontal meridian (arrow)

(UGH) syndrome in this eye in the postoperative period. At one and half year follow-up, his BCVA is 20/25 in OS with well-centered IOL.

## DISCUSSION

Refixation of the same IOL avoids larger anterior incisions and their attendant astigmatism and corneal endothelial cell consequences by retaining the initially implanted IOL. Also, retaining and refixation of same IOL avoids the need of IOL explantation and thus markedly reduce the effective surgical time. Among the previously described techniques, the intralamellar scleral tucking cannot be attempted because of the thick and very flexible haptics of the single piece acrylic IOL.<sup>4</sup> Lorenzo-Guajardo et al used 23-gauge microincisional vitrectomy cannulas for scleral fixation of dislocated one-piece PMMA IOLs successfully requiring cumbersome intraocular manoeuvres.<sup>5</sup> In our technique, temporary externalization of IOL haptic allows easy suture placement in an open environment avoiding cumbersome intraocular manoeuvres. Tying prolene sutures with the haptics without an eye as against the haptics with eyes as designed for scleral fixation could be limitation of this technique. Preservation of capsular bag helped to prevent the occurrence of UGH syndrome,

as there was only limited direct contact of the haptic with the ciliary body.

Thus, sutureless PPV was able to treat the late complication of sutureless cataract surgery, and patient continued to get benefits of sutureless procedure despite the complication. Proper case selection, meticulous surgical approach and competent surgeon are important factors for optimum outcome with this technique.

## REFERENCES

1. Davis D, Brubaker J, Espandar L, Stringham J, Crandall A, Werner L, et al. Late in-the-bag spontaneous intraocular lens dislocation: evaluation of 86 consecutive cases. *Ophthalmol* 2009;116:664-670.
2. Kim SS, Smiddy WE, Feuer W, Shi W. Management of dislocated intraocular lenses. *Ophthalmol* 2008;115:1699-1704.
3. Spirn MJ. Comparison of 25, 23 and 20-gauge vitrectomy. *Curr Opin Ophthalmol* 2009;20:195-199.
4. Kumar DA, Agarwal A, Jacob S, Prakash G, Sivagnanam S. Repositioning of the dislocated intraocular lens with sutureless 20-gauge vitrectomy. *Retina* 2010;30:682-687.
5. López-Guajardo L, Dapena I, Teus MA. Dislocated posterior chamber intraocular lens scleral fixation technique through 23-gauge vitrectomy cannulas. *Ophthalmic Surg Lasers Imaging* 2008;39:429-433.