

## CASE REPORT

# Every Knee is not Osteoarthritic, Spontaneous Avascular Necrosis of the Medial Tibial Condyle

<sup>1</sup>Sanjay Yadav, <sup>2</sup>Chandra Shekhar Yadav, <sup>3</sup>Nishikant Kumar, <sup>4</sup>Ashok Kumar

## ABSTRACT

Avascular necrosis (AVN) of tibial condyles is an uncommon cause of joint degeneration and it may mimic osteoarthritis. The differentiation between spontaneous and secondary osteonecrosis is important for appropriate management. We present here a case of spontaneous avascular necrosis of the medial tibial condyle causing sudden increase in pain; localization to the medial tibial condyle near joint line with exacerbation on weightbearing and varus deformity. We also aim to recapitulate briefly various types and currently available treatment options. In the present case, considering advanced stage of AVN and associated degenerative changes, total knee replacement (TKR) was performed successfully with good outcomes.

**Keywords:** Avascular, Necrosis, Tibial condyle, Total knee arthroplasty.

**How to cite this article:** Yadav S, Yadav CS, Kumar N, Kumar A. Every Knee is not Osteoarthritic, Spontaneous Avascular Necrosis of the Medial Tibial Condyle. *J Postgrad Med Edu Res* 2016;50(1):33-35.

**Source of support:** Nil

**Conflict of interest:** None

## INTRODUCTION

Avascular necrosis (AVN) of knee is an uncommon cause of joint degeneration. Avascular necrosis of tibial condyles especially the medial condyle of tibia is uncommon accounting for about 2% cases and it may mimic osteoarthritis with varus deformity. The differentiation between spontaneous and secondary osteonecrosis is important for appropriate management. We present here a case of spontaneous AVN of the medial tibial condyle causing varus deformity and its management. We also aim to recapitulate briefly various types and currently available treatment options.

## CASE REPORT

A 45-year-old female presented in the outpatient department with the complaints of pain in both the knees for the past 5 years. It was insidious in onset and gradually progressive till there was sudden increase in pain since last 4 weeks. There was no definite history of trauma or any history of mechanical symptoms like locking of the knee. Weightbearing increased the pain. On evaluation prior to surgery, tenderness was localized to the medial aspect of proximal tibia near the joint line. Varus stress test was positive suggestive of varus instability. These findings may suggest ligamentous knee injuries or other soft tissue injuries of the knee. Routine blood investigations were normal. Radiographic evaluation showed stage III changes (Carpintero et al).<sup>1</sup> The medial tibial condyle on right side showed significant bone loss, tibial subluxation and varus deformity with degenerative changes (Fig. 1).

Further evaluation with magnetic resonance imaging (MRI) of knee showed type-B pattern (Lotke et al).<sup>2</sup> T1-weighted image showed low signal intensity in the tibial plateau on the medial side extending to metaphysis. The T2-weighted and fat suppressed images showed increased signal intensity representing subchondral bone marrow edema (Figs 2A to C). The surgical plan of total knee arthroplasty (TKA) was made. Right (TKA) was performed with standard posterior stabilized implant (NRG Scorpio, Stryker Orthopedics).<sup>3</sup> We were able to balance the knee with 8 mm polyethylene insert with femur implant size 5 and tibial implant size 3. Postoperatively, patient was mobilized after 2 days and sutures were removed after 2 weeks. Follow-up X-ray showed well fixed and well-aligned implant without any instability (Fig. 3). Prior consent was obtained from the patient for publication of this work.

## DISCUSSION

Since the first description of spontaneous or idiopathic osteonecrosis of the knee by Ahlback in 1968, it is a well recognized entity.<sup>4</sup> It most commonly affects the medial femoral condyle. Medial tibial condyle accounts for only 2% of the cases.<sup>5</sup> It typically affects older patients (usually > 50 years) with female predominance (3:1). Radiological changes vary with stage and disease severity. Carpintero

<sup>1</sup>Senior Resident, <sup>2</sup>Professor, <sup>3</sup>Senior Research Officer  
<sup>4</sup>Assistant Professor

<sup>1-4</sup>Department of Orthopedics, All India Institute of Medical Sciences, New Delhi, India

**Corresponding Author:** Sanjay Yadav, Senior Resident  
Department of Orthopedics, All India Institute of Medical Sciences, New Delhi, India, Phone: 9560754591, e-mail: drsanjay.pgi@gmail.com

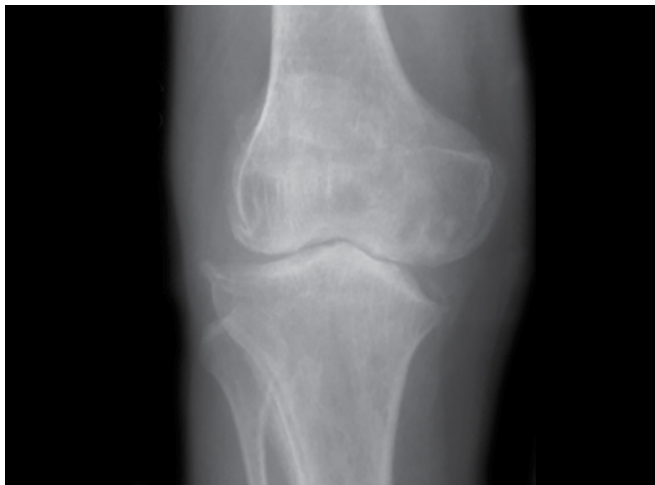
**Table 1:** Staging of osteonecrosis of tibial plateau based on plain radiograph

Stage	Findings
I	Normal radiograph, bone scan and MRI abnormal
II	Cystic and sclerotic changes
III	Fracture of medial rim of medial tibial plateau and tibial plateau collapse
IV	Joint narrowing, genu varum/valgum, lateral tibial plateau involvement

et al (Table 1) have described four stages based on plain radiographs.<sup>1</sup>

Various other staging systems have also been used as developed by Koshino<sup>6</sup> and modified Ficat-Arlet system adapted for the knee.<sup>7</sup>

Size of the initial lesion is an important consideration. Various methods have been described for quantification



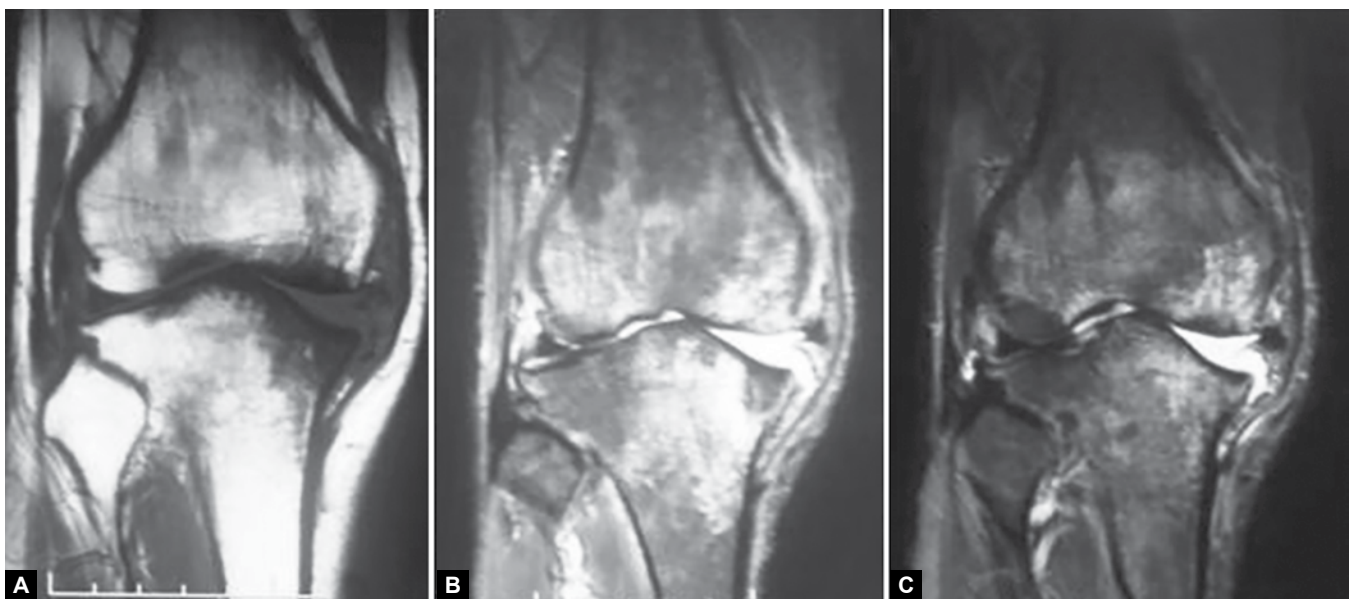**Fig. 1:** Anteroposterior radiograph showing significant collapse of medial tibial condyle, lateral tibial subluxation and associated degenerative changes

of the lesion. Ahlback et al<sup>4</sup> measured the width in millimeters on anteroposterior and lateral radiographs. Aglietti et al<sup>8</sup> measured the ratio with respect to the involved condyle. Mont et al<sup>9</sup> modified the Kerboul angular measurement system for the hip to be applied to the knee. Mont et al also described a system for localizing the lesion by dividing distal femur and proximal tibia into four quadrants.<sup>9</sup>

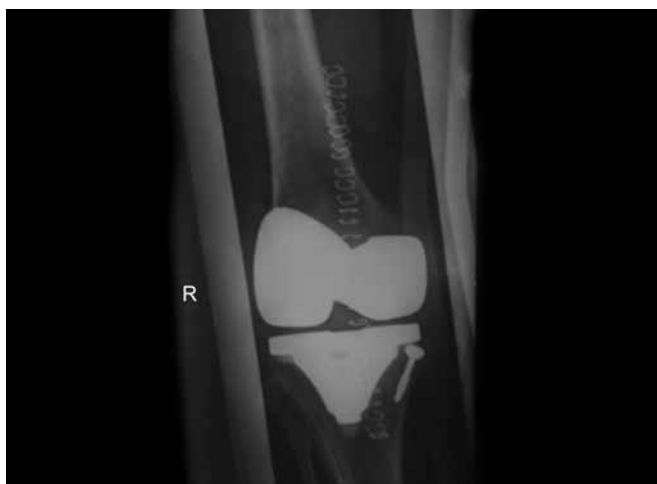Magnetic resonance imaging is very sensitive and specific in diagnosing spontaneous osteonecrosis. Role of bone scan was variable in different studies. Bone scan was not done in our case as it would not have affected the further management. Lotke et al described three types of MRI patterns of osteonecrotic changes.<sup>2</sup> Type A changes were small and well-localized to subchondral area. Type B changes were diffuse and extended up to metaphysis. Type C changes showed well-defined double ring/halo with subchondral collapse.

Treatment options range from nonoperative and joint preserving methods to knee replacement procedures. Nonoperative treatment like protected weightbearing and sole wedges is applicable only to precollapse stage. Our patients rarely present so early. Surgical options include a spectrum from microfracture treatment, osteochondral defect repair, extra-articular core decompression, high tibial osteotomy, unicompartmental knee replacement to total knee replacement.<sup>7</sup> Our patient was initially planned for high tibial osteotomy but due to severe varus collapse and associated degenerative changes, total knee replacement was done.

Osteonecrosis may be associated with osteoporosis or osteopenia. This may result in insufficiency fractures without any traumatic event.<sup>10</sup>



**Figs 2A to C:** Magnetic resonance imaging evaluation: (A) T1-weighted image showing low signal changes in medial tibial condyle, (B and C) T2-weighted and fat suppressed images showing subchondral edema extending to metaphysis and associated joint effusion



**Fig. 3:** Postoperative AP view showing well-fixed implant and screw-cement technique to build up the defect of the medial tibial condyle

Considering outcomes, some studies have shown less promising results following TKR in avascular necrosis. Use of cemented implants in present case may have contributed to good functional and radiological outcome.<sup>11</sup>

In the present case, there was sudden increase in pain during past 1 month; localization was to the medial tibial condyle near joint line with exacerbation on weightbearing. Though age was less than 50 years as compared to the description in literature, other findings and lack of any predisposing factors lead to the diagnosis of spontaneous AVN of medial tibial condyle. Considering advanced stage of AVN and associated degenerative changes, TKR was performed successfully with good outcomes.

## REFERENCES

1. Carpintero P, Leon F, Zafra M, Montero R, Carreto A. Spontaneous collapse of the tibial plateau: radiological staging. *Skeletal Radiol* 2005;34(7):399-404.
2. Lotke PA, Nelson CL, Lonner JH. Spontaneous osteonecrosis of the knee: tibial plateaus. *Orthop Clin N Am* 2004;35(3):365-370.
3. Scorpio NRG Single Radius Primary Knee System Surgical Protocol. Available at: [http://literature.ortho.stryker.com/list/content.php?file\\_name=LSNRGAR\\_ST.pdf](http://literature.ortho.stryker.com/list/content.php?file_name=LSNRGAR_ST.pdf). Accessed on 2013 June 23.
4. Ahlback S, Bauer GC, Bohne WH. Spontaneous osteonecrosis of the knee. *Arthritis Rheum* 1968;11(6):705-733.
5. Jung KA, Lee SC, Hwang SH, Kim DS, Kim TK. Spontaneous osteonecrosis of the knee involving both the medial femoral condyle and the medial tibial plateau: report of three cases. *Knee Surg Sports Traumatol Arthrosc* 2008;16(8):759-762.
6. Koshino T. The treatment of spontaneous osteonecrosis of the knee by high tibial osteotomy with and without bone-grafting or drilling of the lesion. *J Bone Joint Surg Am* 1982;64(1):47-58.
7. Zywiell MG, McGrath MS, Seyler TM, Marker DR, Bonutti PM, Mont M. Osteonecrosis of the knee: a review of three disorders. *Orthop Clin N Am* 2009;40(2):193-211.
8. Aglietti P, Insall JN, Buzzi R, Deschamps G. Idiopathic osteonecrosis of the knee: aetiology, prognosis and treatment. *J Bone Joint Surg (Br)* 1983;65(5):588-597.
9. Mont MA, Baumgarten KM, Rifai A, Bluemke DA, Jones LC, Hungerford DS. Atraumatic osteonecrosis of the knee. *J Bone Joint Surg Am* 2000;82(9):1279-1290.
10. Akamatsu Y, Mitsugi N, Hayashi T, Kobayashi H, Saito T. Low bone mineral density is associated with the onset of spontaneous osteonecrosis of the knee. *Acta Orthop* 2012;83(3):249-255.
11. Mont MA, Rifai A, Baumgarten KM, Sheldon M, Hungerford DS. Total knee arthroplasty for osteonecrosis. *J Bone Joint Surg Am* 2002;84(4):599-603.