

CASE REPORT

Oral Self-mutilation: The Rare Neurological Manifestation in a Case of Japanese Encephalitis

¹Morankar Rahul, ²Sanjeev Singh, ³Gauba Krishan, ⁴Goyal Ashima

ABSTRACT

Self-mutilation is a behavioral disturbance characterized by the deliberate destruction of or damage to body tissues. This case report describes a 7-year-old child reported with multiple ulcerations in the oral cavity due to self-biting. Intraoral examination showed ulcerations on the left and right buccal mucosa and tongue. Medical history revealed history of fever accompanied by acute onset of flaccid paralysis and encephalopathy. Magnetic resonance imaging brain was suggestive of acute viral meningoencephalitis. Japanese encephalitis (JE) infection was confirmed by immunoglobulin M (IgM) detection. The damage due to self-biting was progressive in nature and the patient's condition did not improve on medication. Extractions of permanent teeth were carried out under local anesthesia to prevent the self-injurious behavior (SIB).

Keywords: Japanese encephalitis, Japanese encephalitis virus, Self-injurious behavior.

How to cite this article: Rahul M, Singh S, Krishan G, Ashima G. Oral Self-mutilation: The Rare Neurological Manifestation in a Case of Japanese Encephalitis. *J Postgrad Med Edu Res* 2018;52(3):147-149.

Source of support: Nil

Conflict of interest: None

INTRODUCTION

Japanese encephalitis is one of the leading forms of viral encephalitis worldwide. It is most prevalent in eastern and southern Asia. It is caused by the Japanese encephalitis virus (JEV), which belongs to the family Flaviviridae. Japanese encephalitis virus was first isolated in Japan in 1935.¹ The mosquitoes of *Culex* genus are the major vectors of JEV. Children are commonly affected by the disease. Humans become infected when bitten by an infected mosquito. They are a dead-end host because of low viremia, preventing the virus from being further transmitted.²

Japanese encephalitis typically develops after an incubation period of 5 to 15 days. The disease turns lethal due to failure of the host to produce antibodies against the virus.³ The ability to cross the blood-brain barrier is an important factor for increased pathogenesis and clinical outcome of infection. The JEV on entering the body through a mosquito bite reaches the central nervous system (CNS) via leukocytes, where its virions bind to the endothelial surface of the CNS and are internalized by endocytosis.⁴ The CNS manifestations are a result of neuronal cell death. This occurs either by direct neuronal killing, wherein viral multiplication within neuronal cells leads to cell death, or by indirect killing, due to a massive inflammatory response leading to an upregulation of reactive oxygen species and cytokines leading to neuronal death.⁵

The extent and severity of clinical manifestations caused by JE depend on which part of the nervous system is affected. It includes early symptoms, such as nonspecific febrile illness, diarrhea, and rigor, followed by symptoms, such as reduced levels of consciousness, seizures, headache, photophobia, and vomiting. Later symptoms include flaccid paralysis, generalized hypertonia, rigidity, and other abnormalities in movement. Cognitive and language impairment can be present as neuropsychiatric sequelae in many survivors of JE.⁶

The goal of this case report is to highlight the oral self-mutilation as a rare neurological manifestation in a patient with JE.

CASE REPORT

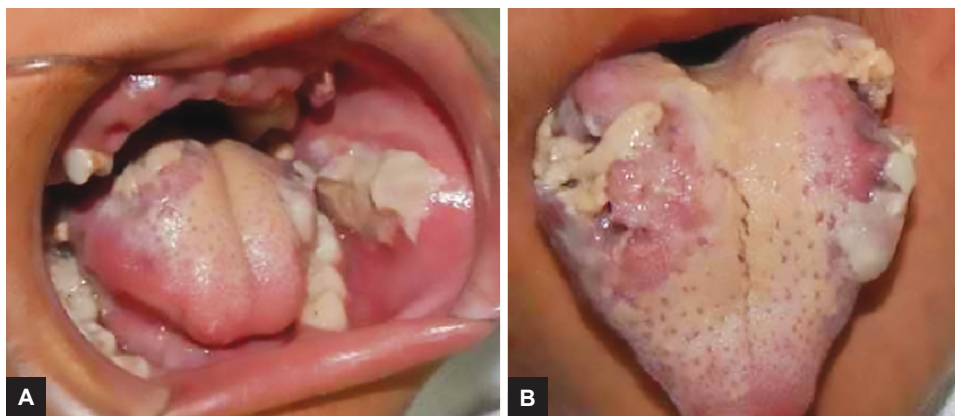
A 7-year-old child reported with a complaint of oral ulcerations on tongue and buccal mucosa due to self-biting. Intraoral examination revealed multiple ulcerations on left and right buccal mucosa along the occlusal plane. The tongue ulcerations were extensive involving dorsum, left and right lateral borders, and ventral surface (Fig. 1).

The medical history was contributory. The child had history of fever followed by vomiting and acute onset of flaccid paralysis and encephalopathy 6 months earlier. The child also had respiratory obstruction and was intubated and ventilated for 2 weeks. Magnetic resonance imaging brain showed a hyperintensity in pons and cerebellum along with cervical and thoracic

¹Senior Resident, ²Junior Resident, ^{3,4}Professor

¹⁻⁴Department of Oral Health Sciences Center, Postgraduate Institute of Medical Education and Research, Chandigarh, India

Corresponding Author: Morankar Rahul, Senior Resident Department of Oral Health Sciences Center, Postgraduate Institute of Medical Education and Research, Chandigarh, India e-mail: captainrahul88@gmail.com



Figs 1A and B: (A) Ulcerations of buccal mucosa along the occlusal plane. (B) Tongue ulcerations involving dorsum, lateral borders, and ventral surface

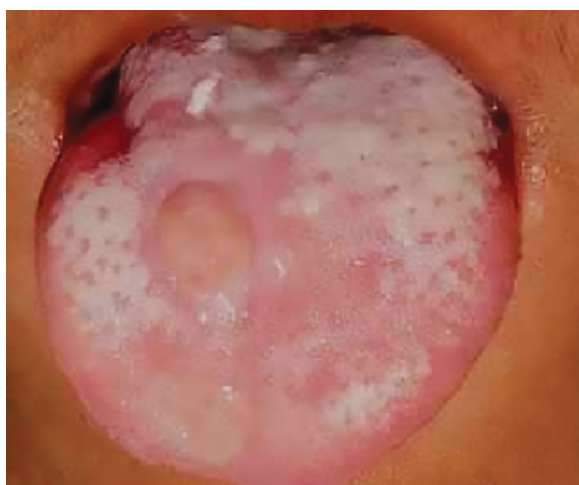

Fig. 2: An improvement in tongue ulcerations following teeth extraction

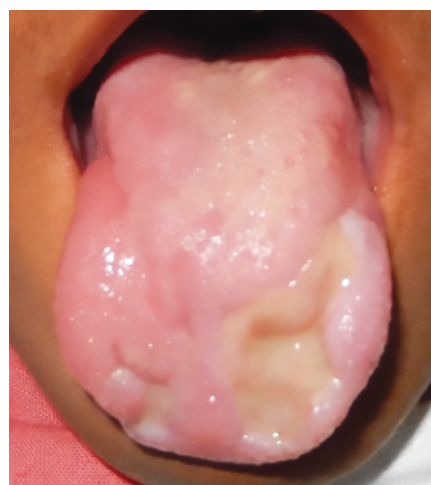

Fig. 3: Oral condition after 8 months follow-up

spinal involvement. The cerebrospinal fluid examination revealed lymphocytosis. A clinical possibility of acute viral meningoencephalitis was considered. Serological confirmation was done using JEV-specific IgM antibodies with enzyme-linked immunosorbent assay kit. The results were positive, confirming the clinical diagnosis.

The patient had recovered apparently well from the condition. Subsequent to that, the child developed SIB and started biting on tongue and cheek. The developmental history of the child was normal and social interactions were appropriate for age before he was affected by the condition. The patient was on antipsychotic and antianxiety medications, i.e., oral risperidone and clonazepam. Despite medication, there was no improvement in the SIB. Initially, the conservative approach was tried and the sharp cusp of teeth was trimmed to decrease the severity of trauma from biting, but it was not useful. Considering the previous history of acute flaccid paralysis and respiratory obstruction, a consultation was sought from the pediatric neurology team for fabrication of an intraoral appliance to protect oral structures from injury due to self-biting. They advised

to avoid the use of any intraoral appliance therapy considering the child’s behavior and fear of aspiration. Thus, extractions of permanent teeth were carried out under local anesthesia to protect the oral structures. An improvement was noticed in the oral wounds following extractions of teeth (Fig. 2). The patient is under regular follow-up. After 8 months, no further worsening of oral condition has been reported (Fig. 3).

DISCUSSION

Self-mutilation is a behavioral disturbance consisting of the deliberate destruction of or damage to body tissues, which is not associated with any conscious intent to commit suicide. Cuts, burns, scratches, blunt injury, and bites are the most common forms of self-injury. The head, oral and perioral tissues, hands, and neck are the most frequently affected anatomical regions. Although prevalence of this behavior in the general population has not been estimated, it has been suggested that it may affect around 750 individuals per 100,000 population.⁷ The reported prevalence among psychiatric patients varies between 21 and 82% and that in mentally retarded

institutionalized individuals is estimated to be between 7.7 and 22.8%.⁸

Simeon and Favazza⁹ classified the SIB into four categories (stereotypic, major, compulsive, and impulsive). Stereotypic behavior, such as self-hitting, face slapping, head banging, hand chewing, and self-biting is seen in organic brain disorder. These are fixed, highly repetitive, biologically driven behavior pattern with mild-to-severe tissue damage, e.g., Lesch–Nyhan syndrome and autism. Individuals with major SIB are insensitive to pain and this can lead to severe and life-threatening tissue injuries, e.g., eye enucleation and limb amputation. These are mostly seen in patients with severe psychotic intoxication. Compulsive SIB shows behavior with mild-to-moderate severity of skin picking, hair pulling, and nail biting. The patient is compelled to execute the impulse, although may wish to resist it. Impulsive SIB tends to be isolated or habitual, characterized by skin cutting, burning, or self-hitting of a mild-to-moderate severity. These are more sporadic and externally triggered.¹⁰

Viral or metabolic encephalitis has been regarded as cause of SIB.¹⁰ Till date, no case report has been published in the literature where JE led to oral self-mutilation. The patient in the present case was developmentally normal until he got infected with JEV. The probable reason for developing SIB could be a neuronal cell death caused by JEV infection leading to pain insensitivity.¹¹

The treatment plan for management of self-inflicting oral injuries depends upon the severity and frequency of biting episodes. A majority of cases improved with medication. Some may require conservative alternatives like acrylic splints or soft resin mouthguards to protect the dentition and oral structures. However, in few cases, such as the one presented in this article, medication and conservative approach remain ineffective and extraction of teeth seems inevitable.

CONCLUSION

Japanese encephalitis can present with various neurological manifestations. Although oral manifestations of this syndrome are not so characteristic, it can be considered as a differential diagnosis in patients with SIB.

REFERENCES

1. Solomon T, Dung NM, Kneen R, Gainsborough M, Vaughn DW, Khanh VT. Japanese encephalitis. *J Neurol Neurosurg Psychiatry* 2000 Apr;68(4):405-415.
2. Solomon T. Flavivirus encephalitis. *N Engl J Med* 2004 Jul;351(4):370-378.
3. Burke DS, Lorsomrudee W, Leake CJ, Hoke CH, Nisalak A, Chongswasdi V, Laorakpongse T. Fatal outcome in Japanese encephalitis. *Am J Trop Med Hyg* 1985 Nov;34(6):1203-1210.
4. Mishra MK, Basu A. Minocycline neuroprotects, reduces microglial activation, inhibits caspase 3 induction, and viral replication following Japanese encephalitis. *J Neurochem* 2008 Jun;105(5):1582-1595.
5. Raung SL, Kuo MD, Wang YM, Chen CJ. Role of reactive oxygen intermediates in Japanese encephalitis virus infection in murine neuroblastoma cells. *Neurosci Lett* 2001 Nov;315(1-2):9-12.
6. Sebastian L, Desai A, Shampur MN, Perumal Y, Sriram D, Vasanthapuram R. N-methylisatin-beta-thiosemicarbazone derivative (SCH 16) is an inhibitor of Japanese encephalitis virus infection in vitro and in vivo. *Virol J* 2008 May;5:64.
7. Briere J, Gil E. Self-mutilation in clinical and general population samples: prevalence, correlates, and functions. *Am J Orthopsychiatry* 1998 Oct;68(4):609-620.
8. Nock MK, Prinstein MJ. A functional approach to the assessment of self-mutilative behavior. *J Consult Clin Psychol* 2004 Oct;72(5):885-890.
9. Simeon D, Favazza AR. Self-injurious behaviors: Phenomenology and assessment, in *Self-Injurious Behaviors: Assessment and Treatment*, eds Simeon D, Hollander E, editors. (Washington, DC: American Psychiatric Publishing;), pp. 1-28.
10. Saemundsson SR, Roberts MW. Oral self-injurious behavior in the developmentally disabled: review and a case. *ASDC J Dent Child* 1997 May-Jun;64(3):205-209, 228.
11. Nabonita S, Anirban B. Japanese encephalitis virus infection: effect on brain development and repair. *Curr Sci* 2013 Sep;105(6):815-820.