

Impending Rupture of Lesser Sac Biloma into the Stomach

Surinder S Rana¹, Rajesh Gupta², Suhang Verma³, Ravi Sharma⁴

ABSTRACT

Biliary injury with bile leak is a well-recognized complication following cholecystectomy. This results in an accumulation of bile within the peritoneal cavity and may manifest with biliary ascites and peritonitis or as a localized collection called biloma. Bilomas are usually intrahepatic or are located in a subhepatic or subphrenic location with the less sac being a rare location for biloma. We present a rare case of a large biloma located in the less sac compressing the stomach. The patient was successfully managed endoscopically by the placement of multiple transmural plastic stents after cannulating and dilating the transmural tract of its impending rupture into the stomach.

Keywords: Biloma, Cholecystectomy, Endoscopy, Endosonography, Stents.

Journal of Postgraduate Medicine, Education and Research (2022); 10.5005/jp-journals-10028-1431

INTRODUCTION

Bilomas are a rare complication of cholecystectomy and occur due to a leak from cystic duct stump, accessory bile duct, or duct of Luschka in the gallbladder fossa.¹ They usually present with abdominal pain, nausea, early satiety, abdominal lump, jaundice, and fever.¹ Bilomas are usually intrahepatic or are located in a subhepatic or subphrenic location.^{1,2} Lesser sac is a rare location for biloma.^{1,2} Symptomatic bilomas are usually treated surgically or by image-guided percutaneous drainage.³ Endoscopic transluminal drainage has been rarely used for treating large bilomas.³ We present a rare case of biloma located in a less sac that was managed endoscopically by cannulating and dilating the transmural tract of its impending rupture into the stomach.

CASE DESCRIPTION

A 37-year-old woman presented with abdominal pain of 7 days duration. Five weeks earlier, she had undergone successful endoscopic retrograde cholangiopancreatography (ERCP), biliary sphincterotomy, and stent placement for post-laparoscopic cholecystectomy cystic duct stump bile leak. Clinical examination revealed a palpable upper abdominal lump. Computed tomography (CT) revealed a large collection in the less sac (Fig. 1). During an endoscopic ultrasound (EUS)—guided transmural drainage of collection, an extrinsic bulge with a yellow-colored ulcer at its summit was noted in the stomach (Fig. 2). Using a duodenoscope, the ulcer was cannulated with an ERCP cannula (Fig. 3). The cannula could be pushed in and aspiration revealed bilious fluid with fluid bilirubin of 26 mg/dL suggestive of biloma. Thereafter, the guidewire was pushed through the cannula and coiled in the collection (Fig. 4). The transmural tract was dilated with a balloon dilator and two 7 Fr double pigtail plastic stents were placed into collection (Fig. 5). ERCP done during the same session revealed normal common bile duct and no extravasation of contrast from the bile duct as well as cystic duct stump was observed. Post procedure, the patient had marked improvement and no collection was observed on magnetic resonance imaging (MRI) of the abdomen done 3 weeks later. The transmural stents were removed 8 weeks later and the patient is asymptomatic after 7 months of follow-up.

¹Department of Gastroenterology, Postgraduate Institute of Medical Education and Research, Chandigarh, India

²⁻⁴Department of Surgical Gastroenterology, Postgraduate Institute of Medical Education and Research, Chandigarh, India

Corresponding Author: Surinder S Rana, Department of Gastroenterology, Postgraduate Institute of Medical Education and Research, Chandigarh, India, Phone: +91-172-2756555, e-mail: drsurinderrana@yahoo.co.in

How to cite this article: Rana SS, Gupta R, Verma S, *et al.* Impending Rupture of Lesser Sac Biloma into the Stomach. *J Postgrad Med Edu Res* 2022;56(2):91–93.

Source of support: Nil

Conflict of interest: None

DISCUSSION

Biliary injury with consequent bile leak is a well-recognized complication following laparoscopic cholecystectomy, occurring in up to 0.3–0.9% of patients.⁴ The most common site of bile leak following cholecystectomy is the cystic duct stump, followed by the duct of Luschka or an accessory bile duct.^{1,5} This results in accumulation of bile within the peritoneal cavity and may manifest with biliary ascites and peritonitis or as a localized collection called biloma.⁶ The proposed mechanism for biloma appears to be the development of a slow bile leak allowing time for fibrosis and encapsulation, while a more rapid leak usually results in biliary ascites and peritonitis.⁷

Biloma usually presents as a well-defined, encapsulated, unilocular and may be intrahepatic or present as extra-organ collections. These are usually evident on cross-sectional imaging and drainage yields a greenish-yellow bilious fluid with elevated fluid bilirubin values.⁸ However, sometimes the contents may be necrotic and frankly purulent resulting in a diagnostic dilemma.⁸ The most common extrahepatic locations of biloma are left or right subphrenic or subhepatic regions.^{1,5} Lesser sac is a rare site for location for biloma.^{1,2} The patients may present with nonspecific symptoms and therefore the diagnosis requires a high degree of clinical suspicion. The majority of cases usually present early, within days to a week following surgery, however, a delayed presentation

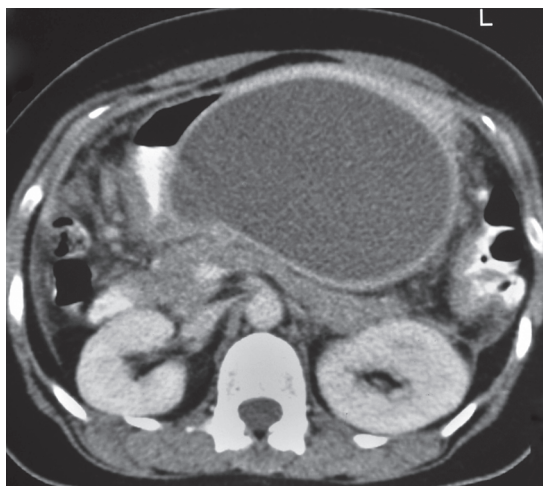


Fig. 1: Computed tomography: large collection in the less sac

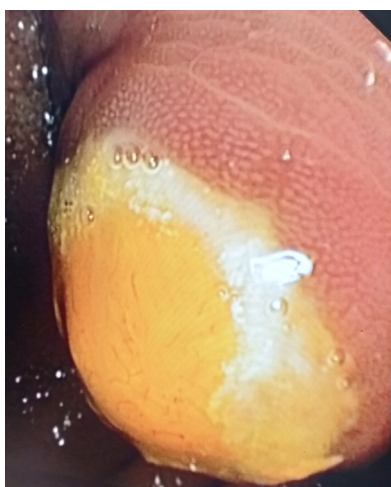

Fig. 2: Extrinsic bulge with a yellow-colored ulcer at its summit noted in the stomach

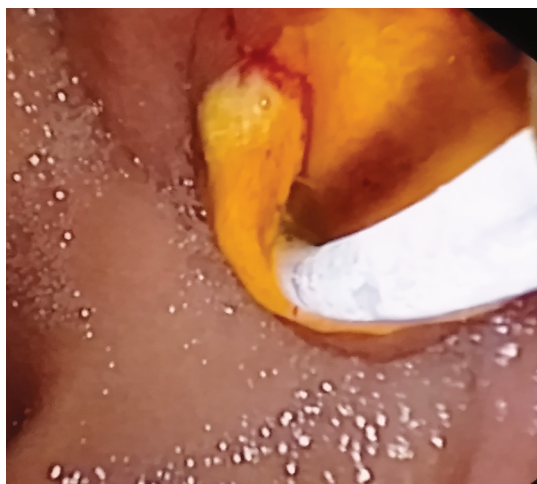


Fig. 3: The ulcer cannulated with ERCP cannula

has also been reported.⁷ Development of abdominal pain, nausea, vomiting, fever, early satiety, jaundice, abdominal lump, or unexplained sepsis during the post-cholecystectomy period should alert the treating physician to the possibility of a biliary injury.^{6,7}

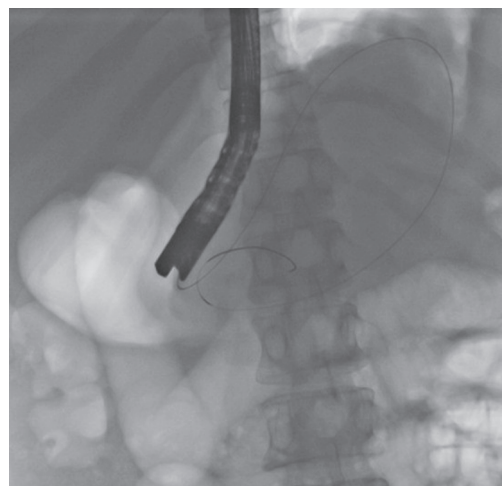


Fig. 4: Guidewire coiled in the collection

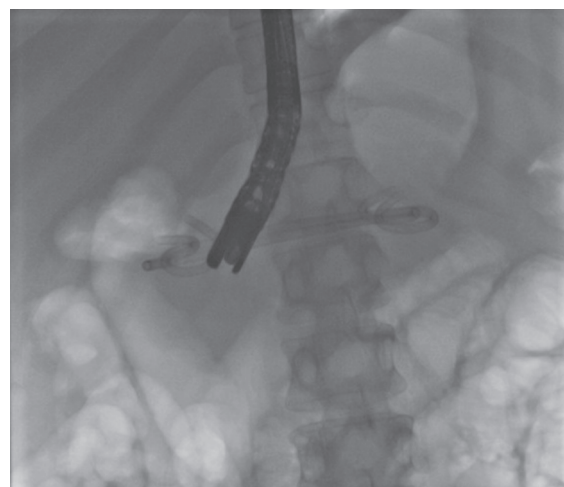


Fig. 5: Two double pigtail plastic stents placed into the collection

Imaging forms the cornerstone for diagnosis, with ultrasonography, CT, or MRI being utilized as initial modalities in suspected cases. The cross-sectional imaging demonstrates an encapsulated fluid collection in characteristic locations.^{4,9} However, the differentiation with other postoperative collections and pseudocyst may sometimes be difficult with cross-sectional imaging alone. Hepatobiliary scintigraphy can be utilized to demonstrate active bile leak and its relationship with biloma while ERCP may be necessary in some cases for diagnosis in addition to its therapeutic role.^{4,9} In nearly half of the cases, active bile leak may not be demonstrable at the time of diagnosis, as was in the index case.⁹ Small asymptomatic biloma may be safely observed and they often resolve spontaneously.^{1,2,6}

Symptomatic bilomas require intervention and have been conventionally treated with surgery or by image-guided percutaneous drainage in conjunction with intravenous antibiotics.⁷ ERCP with transpapillary stent insertion, sphincterotomy, or a combination of both have been used with success in addition to percutaneous drainage in patients with demonstrable bile leaks.⁵ Endoscopic EUS—guided transluminal drainage is an upcoming minimally invasive alternative treatment modality for the management of symptomatic biloma in anatomically suitable and accessible locations.^{3,10} Although reported in a small number of patients, the procedure is feasible, successful, without any

major complications, and avoids insertion of external drains and consequent problems associated with them like pain, infection, and external fistula.¹¹ Transmural drainage is often accompanied by performing ERCP with biliary decompression in the same session. Both transgastric and transduodenal routes with the placement of single/multiple, 7 Fr or 10 Fr double pigtail stents have been utilized for transmural drainage.¹¹ Transmural and transpapillary stents are removed after complete clinical and radiological resolution. No consensus yet exists regarding the type, number, and duration of stent placement due to paucity of data. Our patient had a large symptomatic biloma in the less sac that was compressing the stomach and was about to rupture into the stomach. This large biloma was successfully managed by endoscopically identifying the impending rupture site and subsequent cannulation and dilatation of the transmural tract followed by placement of multiple plastic stents.

In conclusion, the less sac is a rare location for bilomas with endoscopic transmural drainage being a safe and effective therapeutic alternative to percutaneous drainage.

REFERENCES

1. Sharda S, Sharma A, Khullar R, et al. Post-laparoscopic cholecystectomy biloma in the lesser sac: a rare clinical presentation. *J Minim Access Surg* 2015;11(2):154–156. DOI: 10.4103/0972-9941.140215
2. Sisler WJ. Massive biloma in lesser sac of peritoneal cavity after cholecystectomy. *AJR Am J Roentgenol* 1993;160(4):899–900. DOI: 10.2214/ajr.160.4.8456696
3. Baron TH. Combined endoscopic transgastric and transpapillary drainage of an infected biloma. *Endoscopy* 2006;38(4):436. DOI: 10.1055/s-2006-925174
4. Thurley PD, Dhingsa R. Laparoscopic cholecystectomy: postoperative imaging. *Am J Roentgenol* 2008;191(3):794–801. DOI: 10.2214/AJR.07.3485
5. Kaffes AJ, Hourigan L, De Luca N, et al. Impact of endoscopic intervention in 100 patients with suspected postcholecystectomy bile leak. *Gastrointest Endosc* 2005;61(2):269–275. DOI: 10.1016/S0016-5107(04)02468-X
6. Lee CM, Stewart L, Way LW. Postcholecystectomy abdominal bile collections. *Arch Surg* 2000;135(5):538–544. DOI: 10.1001/archsurg.135.5.538
7. Copelan A, Bahoura L, Tardy F, et al. Etiology, diagnosis, and management of bilomas: a current update. *Tech Vasc Interv Radiol* 2015;18(4):236–243. DOI: 10.1053/j.tvir.2015.07.007
8. Mueller P, Ferrucci J, Simeone J, et al. Detection and drainage of bilomas: special considerations. *Am J Roentgenol* 1983;140(4):715–720. DOI: 10.2214/ajr.140.4.715
9. Melamud K, LeBedis CA, Anderson SW, et al. Biliary imaging: multimodality approach to imaging of biliary injuries and their complications. *Radiographics* 2014;34(3):613–623. DOI: 10.1148/rg.343130011
10. Ponnudurai R, George A, Sachithanandan S, et al. Endoscopic ultrasound-guided drainage of a biloma: a novel approach. *Endoscopy* 2006;38(2):199. DOI: 10.1055/s-2006-
11. Shami VM, Talreja JP, Mahajan A, et al. EUS-guided drainage of bilomas: a new alternative? *Gastrointest Endosc* 2008;67(1):136–140. DOI: 10.1016/j.gie.2007.07.040