

CASE REPORT

Juvenile Nasopharyngeal Angiofibroma with Midline Palatal Ulceration: A Rare Presentation

Kanika Arora¹, Manjul Muraleedharan², Sandeep Bansal³

ABSTRACT

Aim: To describe an unusual presentation of juvenile nasopharyngeal angiofibromas (JNAs) in the form of a midline palatal ulceration.

Background: Juvenile nasopharyngeal angiofibromas are benign fibrovascular tumors that usually present with nasal obstruction and epistaxis. They preferably take the paths of least resistance and thereby frank bony erosions are rare.

Case description: A teenaged boy presented with classical features of JNA and midline palatal ulceration with a mass protruding through it, with no previous history of surgical manipulation. After adequate workup, he underwent endoscopic excision of the mass which was postoperatively confirmed to be an angiofibroma.

Conclusion: Rare presentations of a vascular tumor should always be kept in mind while dealing with classical history.

Clinical significance: With nasal obstruction and epistaxis, midline palatal ulcerations should be dealt with caution keeping JNA as a differential; surgical history is of utmost importance.

Keywords: Epistaxis, Juvenile nasopharyngeal angiofibroma, Oral ulceration, Palatal perforation, Unusual presentation.

Journal of Postgraduate Medicine, Education and Research (2021): 10.5005/jp-journals-10028-1436

BACKGROUND

Juvenile nasopharyngeal angiofibromas (JNAs) are rare, benign but locally aggressive nasopharyngeal tumors. They are highly vascular tumors and mostly affect prepubertal and adolescent males.¹ They usually present with unilateral, painless, progressive nasal obstruction, and epistaxis and are also sometimes associated with headache, facial swelling, proptosis, history of chronic sinusitis, and palatal bulge.^{2,3} In this case report, we describe an unusual presentation of JNA, in the form of a fleshy mass in the oral cavity protruding through erosion in the hard palate.

CASE DESCRIPTION

A 16-year-old boy presented with a complaint of intermittent nasal bleed and nasal obstruction which started on the right side, gradually progressing to cause bilateral block with associated watery non-foul smelling nasal discharge, heaviness in the right ear, snoring, right side facial swelling, and mouth breathing. There was also progressive swelling over the hard palate which was smooth to start with, and later ulcerated to form a perforation over the mid-palate. There was no history of any previous surgery and general physical examination was non-contributory except for clinical pallor.

On local examination, there was a soft, diffuse, nontender fullness present over the right side cheek (Fig. 1). Anterior rhinoscopy showed a pale mass in the right nasal cavity with mucoid discharge and gross deviation of the nasal septum toward left, compromising both the cavities and thereby nasal endoscopy could not yield any more information. Oral cavity examination showed a 3 × 3 mm defect in the hard palate, almost at the hard palate-soft palate junction and a 1.5 × 1.5 cm reddish, smooth, soft mass was seen protruding through it and thereby obscuring its margins (Fig. 2).

Further evaluation was done using a CT scan which showed enhancing lesion at posterior choana and nasopharynx

¹⁻³Department of Otolaryngology Head and Neck Surgery, Postgraduate Institute of Medical Education and Research, Chandigarh, India

Corresponding Author: Sandeep Bansal, Department of Otolaryngology Head and Neck Surgery, Postgraduate Institute of Medical Education and Research, Chandigarh, India, Phone: +91 9878001253, e-mail: drsandeepb@rediffmail.com

How to cite this article: Arora K, Muraleedharan M, Bansal S. Juvenile Nasopharyngeal Angiofibroma with Midline Palatal Ulceration: A Rare Presentation. *J Postgrad Med Edu Res* 2021;55(3):136–138.

Source of support: Nil

Conflict of interest: None



Fig. 1: Front profile of patient showing right cheek swelling

compromising the airway. It was extending to the right pterygopalatine fossa, the infratemporal fossa, and the masticator space. The lesion was also seen going through the right inferior orbital fissure into the orbit and causing a widening of the superior orbital fissure, reaching the middle cranial fossa. Erosion and bony remodeling of the palatine bone with an extension of the lesion into the oral cavity can also be well appreciated (Fig. 3). There was no intracranial or intraorbital extension as confirmed by an MRI. The patient based on clinical and radiological findings was diagnosed as JNA—Radkowski Stage III-A.

He underwent endovascular embolization of bilateral internal maxillary arteries with a 60–70% reduction in tumor blush followed by endoscopic excision by modified Denker's approach which made the palatal perforation clearly visible (Fig. 4). Postoperative histopathology confirmed the diagnosis.

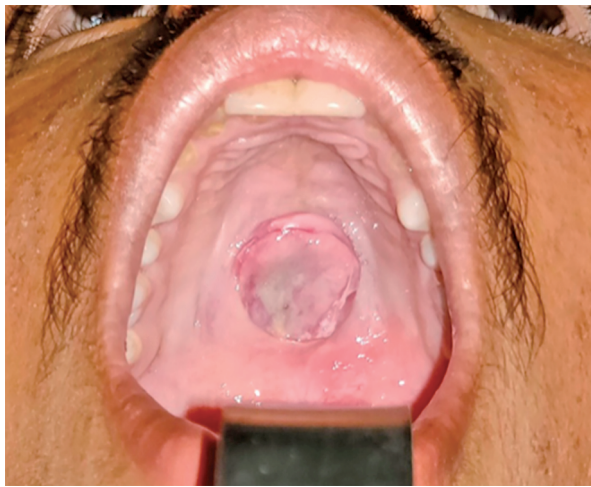

Fig. 2: Smooth fleshy mass seen protruding out of the hard palate

DISCUSSION

Juvenile nasopharyngeal angiofibroma typically presents with nasal obstruction and epistaxis. However, there had been reports in the literature about its unusual and rare presentations like stridor/respiratory distress.^{4,5} This expansile tumor in the nasal cavity tends to cause bony remodeling due to the generated pressure and thereby is often seen to produce facial swelling, deviated septum, and oral bulge but it rarely erodes the bone.

Theories regarding its development are still debated. Most suitable is the one relating it to the pituitary androgen–estrogen axis⁶ followed by theories of various growth factors associated with it.

Juvenile nasopharyngeal angiofibroma is diagnosed by history, clinical examination, nasal endoscopy, and contrast-enhanced CT complemented by angiography and MRI depending upon the extent of the tumor. Management is mainly surgical excision which can be done using endoscopic or open approaches. Other modalities like radiotherapy have been used for residual or unresectable tumors.

Radiology usually shows an enhancing mass traveling through fossa/foramen causing their widening or bowing of walls of maxillary sinus as typically seen in the mentioned case. This is a classical pattern of spread of this benign vascular lesion.⁷

Even though the growth pattern of JNA has always been difficult to understand, it has been considered to grow along the paths of least resistance. But certain authors suggest that the growth routes are decided by the epicenter.⁸

If at all there is palatal erosion in the case of JNA, it might be rare due to the disease as described, or previous surgery is done via transpalatal approach, or as a complication of embolization.⁹

CONCLUSION

Rare presentations of a vascular tumor should always be kept in mind while dealing with classical history.

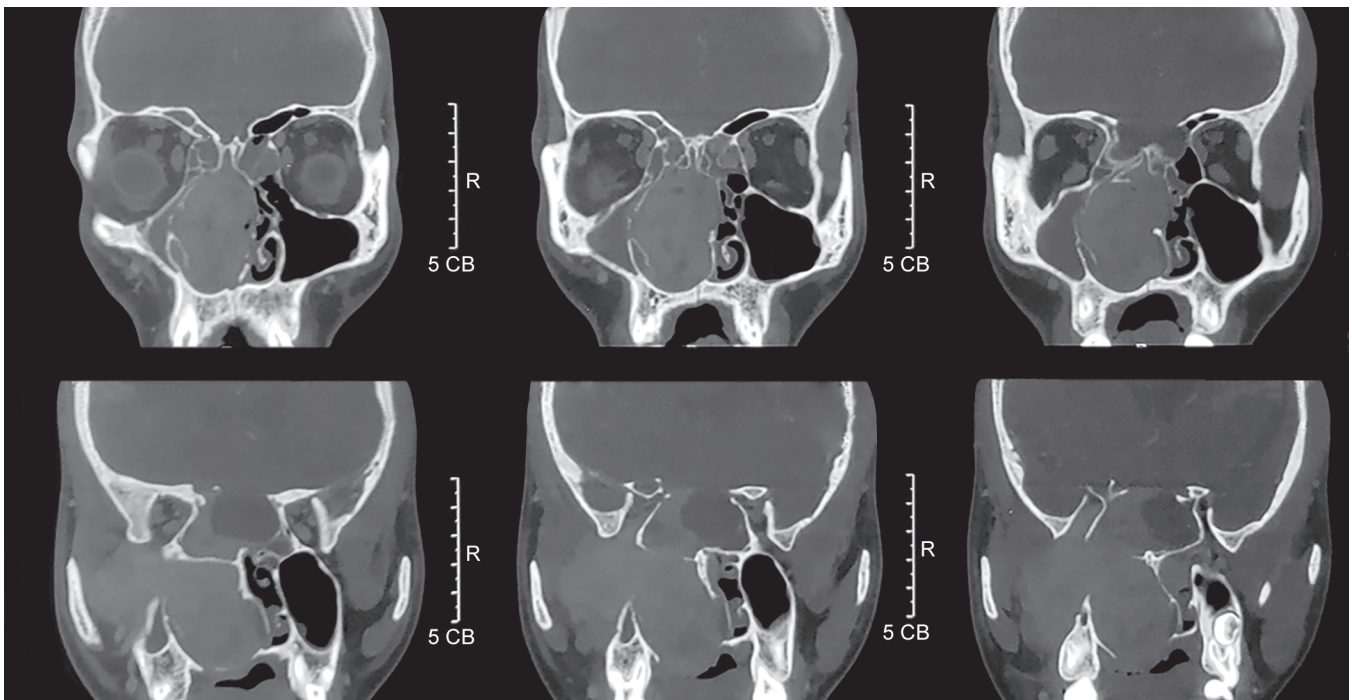


Fig. 3: Coronal view of contrast-enhanced CT scan showing the extent of lesion

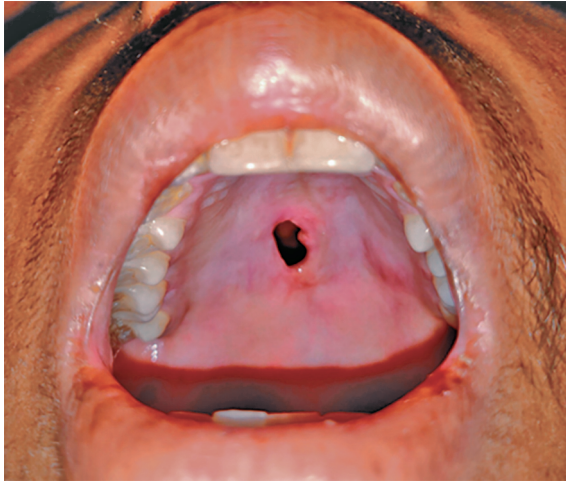

Fig. 4: The perforation of the hard palate as visualized after complete excision of the lesion

CLINICAL SIGNIFICANCE

With associated nasal obstruction and epistaxis which might be of variable severity, midline palatal ulcerations should be dealt with caution during biopsies and JNA should always be kept as a differential.

History of previous surgery is of utmost importance in such cases.

REFERENCES

1. Rubin R, Strayer DS, Rubin E. Rubin's pathology: Clinico-pathologic foundations of medicine. 5th ed., Lippincott Williams & Wilkins; 2008.
2. Kabot TE, Goldman ME, Bergman S, et al. Juvenile nasopharyngeal angiofibroma: an unusual presentation in the oral cavity. *Oral Surg, Oral Med, Oral Pathol* 1985;59(5):453–457. DOI: 10.1016/0030-4220(85)90080-5.
3. Ray P, Mishra SR. Juvenile nasopharyngeal angiofibroma presenting as a palatal swelling. *J Dentis Child* 2014;81(2):91–95.
4. Wheat C, Bickley RJ, Cohen E, et al. Juvenile nasopharyngeal angiofibroma presenting with acute airway obstruction. *Case Rep Otolaryngol* 2016;2016:1537276. DOI: 10.1155/2016/1537276.
5. Singh HP, Kumar S, Vashishtha M, et al. Stridor: an unusual presentation of juvenile nasopharyngeal angiofibroma. *Case Reports* 2014;2014:bcr2013202745.
6. Schiff M. Juvenile nasopharyngeal angiofibroma: a theory of pathogenesis. *Laryngoscope* 1959;69(8):981–1016. DOI: 10.1288/00005537-195908000-00001.
7. Garça MF, Yuca SA, Yuca K. Juvenile nasopharyngeal angiofibroma. *Eur J Gen Med* 2010;7(4):419–425. DOI: 10.29333/ejgm/82897.
8. Liu ZF, Wang DH, Sun XC, et al. The site of origin and expansive routes of juvenile nasopharyngeal angiofibroma (JNA). *Int J Pediat Otorhinolaryngol* 2011;75(9):1088–1092. DOI: 10.1016/j.ijporl.2011.05.020.
9. Wang WH, Lee SS, Wang LF, et al. Repair oronasal fistula in a treated juvenile nasopharyngeal angiofibroma patient. *J Plastic, Reconstruct Aesthe Surg* 2007;60(10):1148–1151. DOI: 10.1016/j.bjps.2006.10.007.