

## CASE REPORT

# Rare Triad of Spontaneous Ovarian Hyperstimulation Syndrome, Ovarian Torsion and Intestinal Obstruction in Pregnancy: Diagnosed with Ultrasound

<sup>1</sup>Tulika Singh, <sup>2</sup>Madhurima Sharma, <sup>3</sup>Upasana Sinha, <sup>4</sup>Seema Chopra, <sup>5</sup>Niranjan Khandelwal

## ABSTRACT

Ovarian hyperstimulation syndrome (OHSS) is a known iatrogenic complication of assisted reproductive techniques. Spontaneous OHSS in the absence of ovulation induction is very rare, which can be more rarely complicated by ovarian torsion. Prompt diagnosis of ovarian torsion is desirable to preserve the viability of ovary. However, the background of OHSS can make it difficult to diagnose ovarian torsion. A careful evaluation of ovary on ultrasound can make a diagnosis of ovarian torsion. Intestinal obstruction is also rare in pregnancy. We describe a rare case of spontaneous OHSS in pregnancy presenting with torsion and intestinal obstruction, which was diagnosed on ultrasound.

**Keywords:** Doppler ultrasonography, Ovarian hyperstimulation syndrome (OHSS), Pregnancy, Torsion, Ultrasonography (USG).

**How to cite this article:** Singh T, Sharma M, Sinha U, Chopra S, Khandelwal N. Rare Triad of Spontaneous Ovarian Hyperstimulation Syndrome, Ovarian Torsion and Intestinal Obstruction in Pregnancy: Diagnosed with Ultrasound. *Journal of Postgraduate Medicine, Education and Research*, Oct-Dec 2018;52(4): 183-186.

**Source of support:** Nil

**Conflict of interest:** None

## INTRODUCTION

Ovarian hyperstimulation syndrome (OHSS) is a rare complication of ovulation induction. It is usually iatrogenic occurring in women undergoing assisted reproductive therapies. OHSS can rarely occur spontaneously in the absence of ovulation induction, and this is generally seen in women with the polycystic ovarian syndrome (PCOS), hypothyroidism and multiple pregnancies.<sup>1-7</sup> Only a few cases of spontaneous OHSS have been reported in the literature.

<sup>1,3,4</sup>Associate Professor, <sup>2</sup>Senior Resident, <sup>5</sup>Professor

<sup>1,2,5</sup>Department of Radio Diagnosis, Postgraduate Institute of Medical Education and Research, Chandigarh, India

<sup>3</sup>Department of Radio Diagnosis, Government Medical College and Hospital, Chandigarh, India

<sup>4</sup>Department of Obstetrics and Gynecology, Postgraduate Institute of Medical Education and Research, Chandigarh, India

**Corresponding Author:** Tulika Singh, Associate Professor, Department of Radio Diagnosis, Postgraduate Institute of Medical Education and Research, Chandigarh, India, e-mail: tulikardx@gmail.com

Ovarian torsion is a rare complication of OHSS, which needs prompt diagnosis and treatment for preservation of ovarian function. But the classic signs and symptoms of ovarian torsion may be obscured by the OHSS. However, ultrasonography with Doppler study can demonstrate the features of ovarian torsion in enlarged ovaries of OHSS. Intestinal obstruction in pregnancy is also rare. There is only a single case report of OHSS secondary to *in vitro* fertilization (IVF) in pregnant woman complicated by both ovarian torsion and small bowel obstruction.<sup>8</sup> We report a rare case of spontaneous OHSS in a normal singleton pregnancy complicated by ovarian torsion and intestinal obstruction, which was diagnosed by the ultrasound. To our knowledge, this is the first case report in the literature describing a triad of spontaneous OHSS, ovarian torsion, and intestinal obstruction.

## CASE REPORT

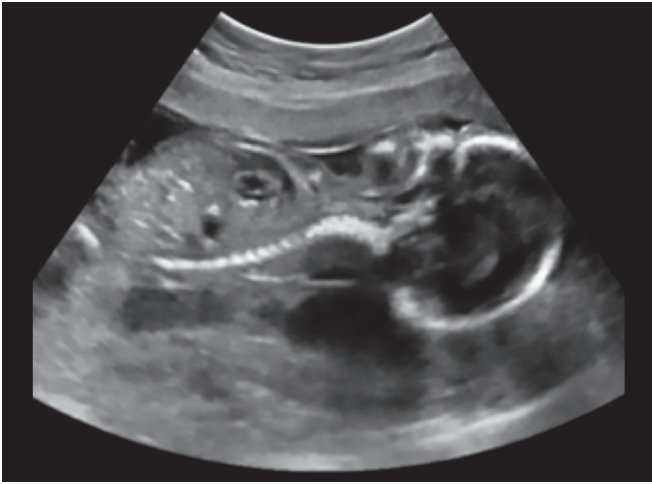A 26-year-old primigravida presented at 18 weeks of gestation in a gynecological emergency of our institute with the complaints of acute pain abdomen, abdominal distension, vomiting and constipation for 1 week. There was no history of fever, vaginal bleeding or any infertility treatment. No significant medical history was present.

On initial examination, she was afebrile (36.3° C) and hemodynamically stable (blood pressure 112/76 mm of Hg, heart rate-78 per minute, respiratory rate-186 per minute) with oxygen saturation 100% on room air. The general physical examination was unremarkable.

On local examination, the abdomen was soft, with no signs of peritonitis. Tenderness was present in the right iliac fossa. Cardiovascular and respiratory system examinations were within normal limits.

Initial laboratory tests revealed normal hematocrit and hemoglobin (11 gm%) with leukocytosis (total leucocyte count-16 X 10<sup>3</sup> per dL). Renal function tests and liver function tests were within normal limits. On evaluation, the patient was found to have decreased T3 and T4 blood levels with markedly elevated TSH (58 micros IU/mL) suggestive of primary hypothyroidism.

Ultrasonography (USG) showed a single live intrauterine fetus of gestational age 18 weeks (Fig. 1). Fetal parameters were in accordance with gestational age with no evidence of any gross congenital malformation.



**Fig. 1:** Grayscale ultrasound image showing the single intrauterine fetus

There was asymmetrical enlargement of both ovaries (right more than left) with the right ovary measuring about 11.5 x 10 x 7.7 cm (Fig. 2A) and the left ovary measuring approximately 8 x 3.8 x 4.4 cm (Fig. 2B). Both the ovaries showed multiple peripherally arranged follicles.

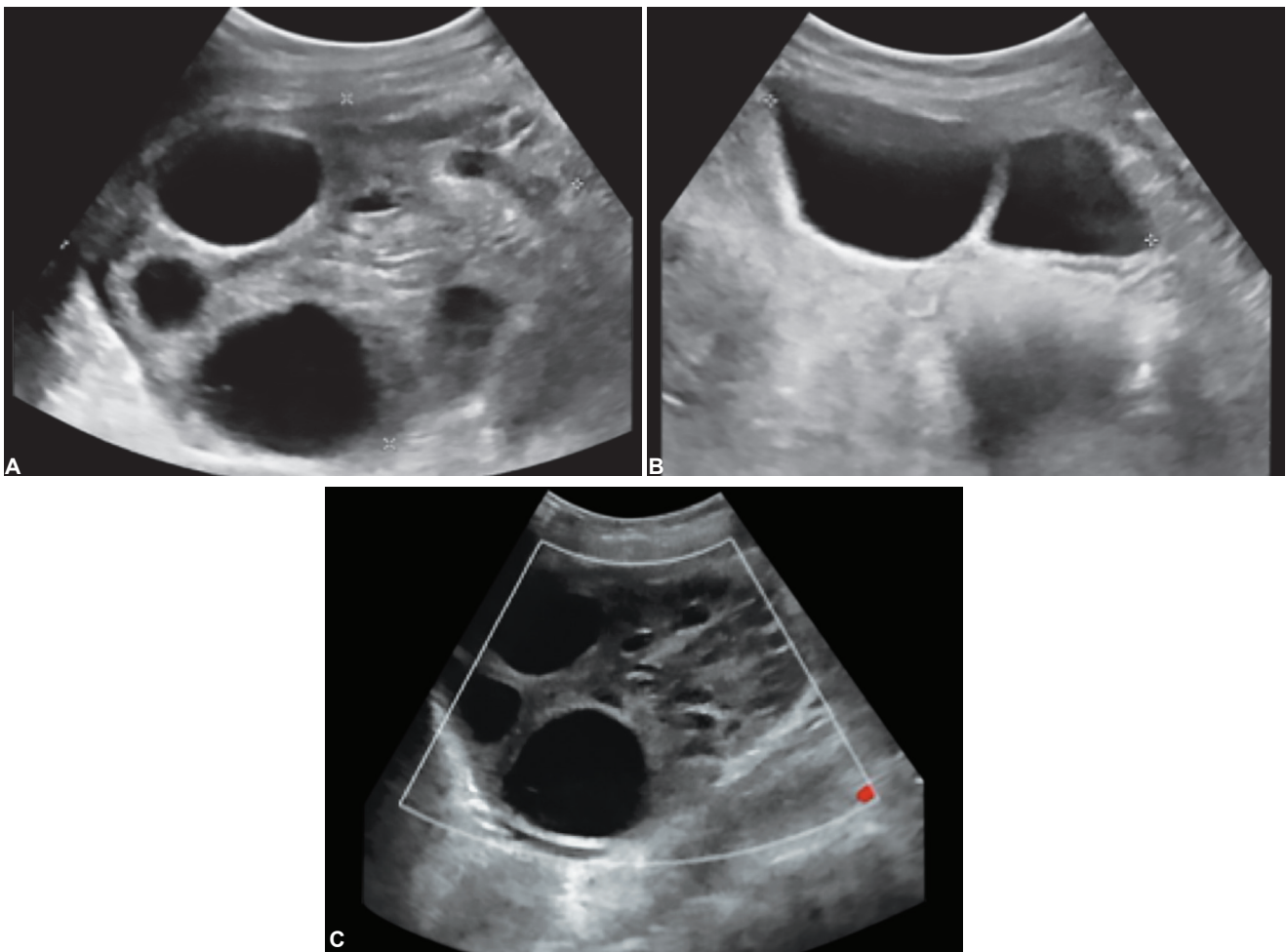
Right ovary showed increased and heterogeneous stromal echogenicity with absent vascularity on

Doppler examination (Fig. 2C). Thus the possibility of OHSS with right ovarian torsion was given. Ultrasound also revealed dilated small bowel loops (measuring ~ 3.2cm in maximum caliber) with decreased peristalsis, showing to and fro motion of intestinal contents consistent with intestinal obstruction (Fig. 3). However, no definite transition point was identified on ultrasound. There was no evidence of appendicitis or acute cholecystitis.

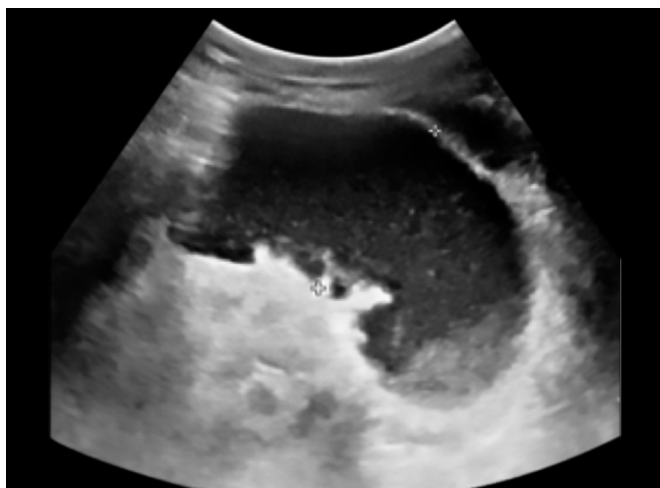
Initially, a patient was started on oral thyroxine and was managed conservatively. Subsequently, her intestinal obstruction was relieved. But because of the persistent pain in her abdomen, she was taken for laparotomy, which showed enlarged gangrenous right ovary with double twisted right ovarian ligament suggestive of ovarian torsion. Right salpingo-oophorectomy was performed. The patient was discharged in stable condition with a viable pregnancy.

## DISCUSSION

The incidence of OHSS has increased due to the increasingly common use of IVE. A mild degree of OHSS occurs



**Figs 2A to C:** (A) Grayscale ultrasound image showing an enlarged right ovary with peripherally arranged cysts and heterogenous stromal echogenicity, B) The left ovary was also enlarged with few cysts, (C) On color Doppler, no vascularity was seen in right ovary



**Fig. 3:** Ultrasound image showing dilated ileal loop

in 33% of in IVF cycles, and 3 to 8% of IVF cycles are complicated by moderate or severe OHSS.<sup>9</sup> Spontaneous OHSS is rare and can occur in PCOS, hypothyroidism and multiple pregnancies.<sup>1-7</sup> Our case has a spontaneously conceived pregnancy with severe hypothyroidism. In hypothyroidism, the elevated concentrations of stimulating thyroid hormone may mediate ovarian hyperstimulation because of the presence of nuclear thyroid receptors (TR and TR $\beta$ ) in the granulosa cells.<sup>3</sup>

Diagnosis of OHSS is based upon clinical presentation and is divided into mild, moderate, severe and critical.<sup>10</sup> Abdominal bloating is often the presenting symptom due to increase in ovarian size. There is a shift of fluid from intravascular to extravascular compartment leading to ovarian cysts, ascites, pleural effusion, and hemoconcentration. Ovarian torsion is difficult to diagnose on a background of OHSS, due to nonspecific symptoms. Abdominal pain, nausea, and vomiting are often suspicious for ovarian torsion.<sup>11</sup>

Ultrasound in OHSS typically shows bilateral symmetrical enlargement of ovaries with multiple cysts of varying sizes, giving the classic spoke wheel appearances. There may be an associated ascites, pleural and pericardial effusions. OHSS acts as a predisposing factor for torsion due to increased adnexal volume and weight.<sup>12</sup>

Grayscale ultrasound along with color Doppler is the initial imaging modality used in cases of suspected ovarian torsion. Grayscale ultrasound shows unilateral enlarged hypo or hyperechoic ovary with peripherally displaced follicles. Doppler study shows little or no intraovarian venous flow, absent arterial flow and absent or reversed diastolic flow. However normal vascularity does not exclude torsion. A false negative rate of 61% has been reported for Doppler diagnosis of ovarian torsion in pregnancy.<sup>13</sup> Thus, the decision for surgical management should be based upon clinical and laboratory findings as well as past medical history of the patient in addition

to Doppler findings. Whirlpool sign of twisted vascular pedicle may be seen.<sup>14</sup> In case of equivocal USG or nonvisualization of ovaries because of displacement by gravid uterus, noncontrast magnetic resonance imaging (MRI) can also be performed in pregnant women which also shows enlarged edematous ovary with peripherally displaced follicles, twisted pedicle, and areas of ovarian hemorrhages.<sup>8</sup>

We have reported a rare case of spontaneous ovarian hyperstimulation in a pregnant patient with hypothyroidism, presenting as an acute emergency with ovarian torsion and intestinal obstruction. In this case, ultrasonography played a key role in diagnosing ovarian hyperstimulation and ovarian torsion. Dilated small bowel loops were also well seen on ultrasound. Ovarian torsion is an extremely rare cause of intestinal obstruction with only one case described in the literature.<sup>8</sup> However in our case, the obstruction was subacute and was relieved by conservative management. Intraoperative findings showed enlarged ovary closely adherent to small bowel loops. So we inferred that compression by enlarged ovary was the cause of subacute intestinal obstruction.

Though OHSS is easily diagnosed on ultrasound, ovarian torsion in OHSS may pose diagnostic difficulty, as both ovaries are enlarged with peripheral follicles. Asymmetrical enlargement of one ovary with heterogeneous echogenicity (because of hemorrhage) on grayscale ultrasound and reduced or absent flow on color doppler help in making a diagnosis of ovarian torsion on the background of OHSS.

The first line of treatment for ovarian torsion is laparoscopic derotation, even in ischemic ovaries.<sup>11</sup> The complete absence of blood flow is an indication for adnexectomy. Anesthetic management of ovarian torsion during pregnancy is also challenging. Regional anesthesia avoids the risk of failed intubation and aspiration and also reduces fetal exposure to potential teratogens.<sup>15</sup> Appropriate care should be taken to maintain normal maternal physiological function and uteroplacental blood flow during the intraoperative period.

To conclude, ultrasonography is the modality of choice to diagnose ovarian hyperstimulation syndrome and ovarian torsion in pregnancy. The radiologist should be familiar with imaging features of ovarian torsion. Ovarian torsion should be suspected in a case of OHSS whenever there is asymmetrical enlargement of one ovary with the absent or reduced flow.

## REFERENCES

1. Cardoso CG, Graça LM, Dias T, Clode N, Soares L. Spontaneous ovarian hyperstimulation and primary hypothyroidism with a naturally conceived pregnancy. *Obstetrics & Gynecology*. 1999 May 1;93(5):809-811.

2. Nappi RG, Di Naro E, D'aries AP, Nappi L. Natural pregnancy in hypothyroid woman complicated by spontaneous ovarian hyperstimulation syndrome. *American journal of obstetrics and gynecology*. 1998 Mar 1;178(3):610-611.
3. Borna S, Nasery A. Spontaneous ovarian hyperstimulation in a pregnant woman with hypothyroidism. *Fertility and sterility*. 2007 Sep 1;88(3):705-e1.
4. Edwards-Silva RN, Han CS, Hoang Y, Kao LC. Spontaneous ovarian hyperstimulation in a naturally conceived pregnancy with uncontrolled hypothyroidism. *Obstetrics & Gynecology*. 2008 Feb 1;111(2):498-501.
5. Zalel Y, Orvieto R, Ben-Rafael Z, Homburg R, Fisher O, Insler V. Recurrent spontaneous ovarian hyperstimulation syndrome associated with polycystic ovary syndrome. *Gynecological Endocrinology*. 1995 Jan 1;9(4):313-315.
6. Chae HD, Park EJ, Kim SH, Kim CH, Kang BM, Chang YS. Case report: ovarian hyperstimulation syndrome complicating a spontaneous singleton pregnancy: a case report. *Journal of assisted reproduction and genetics*. 2001 Feb 1;18(2):120-123.
7. Agrawal NR, Gupta G, Verma K, Varyani N. Spontaneous ovarian hyperstimulation syndrome in a triplet pregnancy. *Case reports in critical care*. 2012.
8. Lazaridis A, Maclaran K, Behar N, Narayanan P. a rare case of small bowel obstruction secondary to ovarian torsion in an Ivf pregnancy: ep1. 384. *Bjog: An International Journal of Obstetrics and Gynaecology*. 2013 Jun 1;120:173.
9. Royal College of Obstetricians and Gynaecologists. The Management of Ovarian Hyperstimulation Syndrome. Green-top Guideline No. 5. Sep 2006.
10. Wallach EE, Navot D, Bergh PA, Laufer N. Ovarian hyperstimulation syndrome in novel reproductive technologies: prevention and treatment. *Fertility and Sterility*. 1992 Aug 1;58(2):249-261.
11. Spitzer D, Wirleitner B, Steiner H, Zech NH. Adnexal torsion in pregnancy after assisted reproduction—case study and review of the literature. *Geburtshilfe und Frauenheilkunde*. 2012 Aug;72(08):716-720.
12. Speroff L, Fritz MA, editors. *Clinical gynecologic endocrinology and infertility*. lippincott Williams and wilkins; 2005: 1183.
13. Hasson J, Tsafir Z, Azem F, Bar-On S, Almog B, Mashiach R, et al. Comparison of adnexal torsion between pregnant and nonpregnant women. *American journal of obstetrics and gynecology*. 2010 Jun 1;202(6):536-e1.
14. Chang HC, Bhatt S, Dogra VS. Pearls and pitfalls in diagnosis of ovarian torsion. *Radiographics*. 2008 Sep;28(5):1355-1368.
15. Rashmi HD, Raghavendra TR, Komala HK, Vinutha DK, Chaithra GV. Anesthetic management of a patient with torsion of ovarian cyst in the third trimester of pregnancy. *International Journal of Medical Science and Public Health*. 2015;4(10): 1473-1476.